



Advances in local therapy for glioblastoma — taking the fight to the tumour

Thomas S. van Solinge^{1,2}✉, Lisa Nieland^{1,2}, E. Antonio Chiocca³
and Marike L. D. Broekman^{1,2,4}

Abstract | Despite advances in neurosurgery, chemotherapy and radiotherapy, glioblastoma remains one of the most treatment-resistant CNS malignancies, and the tumour inevitably recurs. The majority of recurrences appear in or near the resection cavity, usually within the area that received the highest dose of radiation. Many new therapies focus on combatting these local recurrences by implementing treatments directly in or near the tumour bed. In this Review, we discuss the latest developments in local therapy for glioblastoma, focusing on recent preclinical and clinical trials. The approaches that we discuss include novel intraoperative techniques, various treatments of the surgical cavity, stereotactic injections directly into the tumour, and new developments in convection-enhanced delivery and intra-arterial treatments.

Glioblastoma remains one of the most lethal neurological malignancies despite decades of unrelenting effort by the research and medical communities to combat this disease. Few new therapies have shown efficacy for mitigating glioblastoma since the introduction of temozolomide as part of the Stupp standard of care protocol in 2005 (REF.¹). Before the Stupp protocol was introduced, median survival was around 12 months, which has since increased to 16 months owing to various improvements in treatment, including optimization of the Stupp protocol, advances in imaging and radiotherapy, and gross total resection safeguarded by intraoperative mapping^{2,3}. In addition, tumour treating fields therapy, in which mitosis is hindered by alternating electric fields, has produced improvements in long-term overall survival (OS) in patients with primary or recurrent glioblastoma^{4,5}.

Although these improvements are encouraging, the long-term prospects for patients with glioblastoma remain extremely poor. The absence of new treatment modalities for glioblastoma cannot be attributed to lack of effort: currently, 1,593 trials are registered under “glioblastoma” on ClinicalTrials.gov. The resistance of glioblastoma to treatment is widely known and can be explained by several distinctive characteristics of the tumour. Glioblastoma is notoriously heterogeneous, with an abundance of signalling pathways even within the same tumour mass, thereby limiting the options for targeted therapies^{6,7}. The tumour microenvironment strengthens the resistance of glioblastoma to radiation and chemotherapy⁸, and the low immunogenicity of glioblastoma hinders a strong immunological

response⁹. In addition, infiltration of glioma (stem) cells deep into the brain excludes effective treatment by resection alone¹⁰. Moreover, the blood–brain barrier (BBB) prevents many systemically administered chemotherapeutics from reaching sufficient concentrations in the brain without serious adverse effects.

At present, finding a cure for glioblastoma remains a distant prospect, and efforts have instead been focused on delaying recurrence. Approximately 80% of glioblastoma recurrences arise inside or at the margin of the radiation field, and this local recurrence is associated with substantially shortened progression-free survival (PFS)¹¹. Furthermore, the extent of resection is a crucial outcome variable: patients who have undergone gross total resections have significantly longer OS than patients with subtotal resections¹². Some centres have demonstrated further improvements in outcomes after supratotal resections¹³, but more evidence is required to substantiate these claims¹⁴. Together, these findings suggest that the resection cavity is an important location to prevent early tumour recurrence. In addition, the isolation of the brain by the BBB creates a unique opportunity to deliver aggressive treatment locally with a limited risk of systemic toxicity.

In this Review, we discuss current and future local therapies for glioblastoma, examining treatment of the tumour cavity (FIG. 1) and other direct approaches to the tumour (FIG. 2). We highlight landmark studies to provide an overview of local therapies that have been — or are currently being — explored in patients with glioblastoma.

¹Departments of Neurology and Radiology, Massachusetts General Hospital, and NeuroDiscovery Center, Harvard Medical School, Boston, MA, USA.

²Department of Neurosurgery, Leiden University Medical Center, Leiden, Netherlands.

³Harvey Cushing Neuro-Oncology Laboratories, Department of Neurosurgery, Brigham and Women's Hospital, Harvard Medical School, Boston, MA, USA.

⁴Department of Neurosurgery, Haaglanden Medical Center, The Hague, Netherlands.

✉e-mail: tsvansolinge@gmail.com

<https://doi.org/10.1038/s41582-022-00621-0>

Key points

- Glioblastoma almost always recurs at or near the resection cavity, within the radiotherapy field.
- Local therapy provides a unique opportunity to deliver high doses of therapeutics to the area with the highest concentration of glioblastoma cells, with limited systemic adverse effects.
- Many phase I and II trials experimenting with various forms of local therapy have been — and are being — conducted in glioblastoma, with many showing great potential for improving progression-free and overall survival.
- Large randomized phase III trials comparing local therapies with standard of care have been hindered by high cost, labour intensity and challenges in patient recruitment.
- Close collaboration between clinicians, researchers, companies and governmental institutions is needed to smooth the transition from laboratory to phase I and II trials to large-scale randomized controlled trials.

Intraoperative treatment modalities

Over the years, many tools have been introduced to aid the surgeon in the resection of lesions in the brain. Inventions such as surgical microscopes, high-resolution imaging, fluorescence-guided surgery and neuro-navigation are widely used in neurosurgery and are beyond the scope of this Review. In this section, we discuss new intraoperative treatments that aid direct destruction of malignant tissue at the time of surgery, can disrupt the BBB and can enhance the immune response after surgery.

Localized thermal therapy

Thermal therapy is based on the ability of heat to induce apoptosis and necrosis in the brain¹⁵. Both in vitro and animal studies have shown that glioma cells are especially vulnerable to heat¹⁶, an effect that is probably enhanced in patients by the relatively fragile neovasculature and the hypoxic microenvironment of glioblastomas¹⁷. Aside from direct apoptosis and necrosis, hyperthermia can sensitize glioma cells to radiation therapy¹⁸ and chemotherapy¹⁹, trigger an immune response²⁰ and provide transient BBB disruption¹⁵. Currently, three methods — laser interstitial thermal therapy (LITT), magnetic hyperthermia and focused ultrasound (FUS) — are at various stages of regulatory approval for local treatment of glioblastoma.

Laser interstitial thermal therapy. In LITT, an optical fibre is stereotactically inserted into the tumour through a burr hole (FIG. 1a). The tissue is then heated with laser light (at a wavelength of 1,064 nm or 980 nm depending on the system)²¹ to 42.5–45.5 °C for several minutes while MRI thermometry is employed to monitor the temperature in the lesion in real time²². Constant monitoring is vital, as the optical properties of tissue vary, especially in tumours. LITT has been in development since the early 1990s, and various studies have assessed its safety and efficacy for treating glioblastoma²². Although safety and targeting have improved with the introduction of intraoperative MRI thermometry, randomized clinical trials of LITT for glioblastoma have not been forthcoming. A retrospective analysis compared 24 patients treated with LITT for primary glioblastoma with a control cohort, matched for gender, age, tumour size and location, who had undergone biopsy only²³ (TABLE 1).

No differences in PFS or OS were observed, but four of the 24 patients treated with LITT experienced permanent worsening of their neurological symptoms. Similarly, in 54 patients treated with LITT for primary or recurrent glioblastoma, 15.5% developed serious adverse events, such as cerebral oedema, seizures and hydrocephalus, with two patients dying within 30 days of surgery, and OS did not improve²⁴ (TABLE 1).

Balancing treatment effectiveness against adverse effects is a challenge in LITT. The extent of ablation seems to be an important determinant of efficacy: near-total ablation correlated with improved PFS and OS in individual studies^{23,25} and in a literature review²¹. The increased aggressiveness of the treatment is likely to increase the risk of adverse effects, with complication rates as high as 33% in one review focused on newly diagnosed glioblastoma²⁶. Currently, LITT might benefit patients with tumours that are inoperable owing to location or poor functional status, and could also have cost-effectiveness advantages in selected patient groups^{27,28}. However, well-designed trials are needed to assess the true efficacy of LITT, possibly in combination with other treatments. Several trials are underway or have recently been completed, studying LITT in combination with anti-PD1 therapy (ClinicalTrials.gov NCT03341806 and NCT03277638), radiotherapy (NCT04181684), lomustine (NCT03022578) or the Stupp protocol (NCT02970448).

Magnetic hyperthermia. Magnetic hyperthermia is a technique in which heat is generated by stimulating magnetic nanoparticles within the tumour or resection cavity with an external alternating magnetic field (FIGS 1b,2a). Repeated cycles of thermotherapy can be administered without additional surgery, and the treatment has the potential to synergize with radiotherapy or chemotherapy. A prospective phase II trial examined the feasibility of magnetic hyperthermia in 59 patients with recurrent glioblastoma²⁹. Iron oxide nanoparticles were injected into the tumour using a stereotactic frame, and six semi-weekly 1-h thermotherapy sessions were combined with stereotactic radiotherapy to a total of 30 Gy (TABLE 1). Possible improvements in survival were found, although some patients experienced adverse effects, such as seizures during treatment or worsening of motor disturbances after treatment²⁹.

An alternative approach is to line the resection cavity with superparamagnetic iron oxide nanoparticles after resection. In a phase I trial in six patients with recurrent glioblastoma, a paste containing these particles was administered to the resection cavity after removal of the tumour³⁰ (TABLE 1). The participants also received 60 Gy stereotactic radiotherapy. No notable adverse effects were observed immediately after six rounds of treatment, but 2–5 months later, all patients had developed a tumour flare reaction with prominent oedema around the nanoparticles. As a result, all patients required high-dose corticosteroids, and four of the six underwent repeat craniotomy to remove the particles. Surgery relieved the acute symptoms but most patients required long-term corticosteroids to fully suppress the oedema. Histological analysis and flow cytometry

of tissue acquired during removal of the beads showed increased infiltration of CD8⁺ T cells, CD4⁺ T cells and CD63⁺ macrophages in areas containing large numbers of nanoparticles, indicating that an immune response had been triggered³⁰.

Like LITT, magnetic hyperthermia is still in its infancy. Adverse effects are common, can be severe and are poorly understood, and efficacy has not been convincingly demonstrated. Intracavitary magnetic hyperthermia seems to induce a potent inflammatory response, and as glioblastomas are known to be immunologically 'cold' tumours, this therapy might help improve the immune response and/or the efficacy

of immune therapies³¹. At present, however, the mechanisms and optimal treatment strategies remain to be fully elucidated. A new phase I trial is currently being developed to identify the optimal temperature (45°C, 50°C or 55°C) for intracavitary treatment in recurrent glioblastoma³⁰.

Focused ultrasound. FUS is rapidly emerging as an exciting new tool to treat a wide range of neurological diseases³². In the case of glioblastoma, efforts are mainly concentrated on using FUS to transiently disrupt the BBB, thereby improving the delivery of chemotherapies that normally show poor diffusion across the BBB³³.

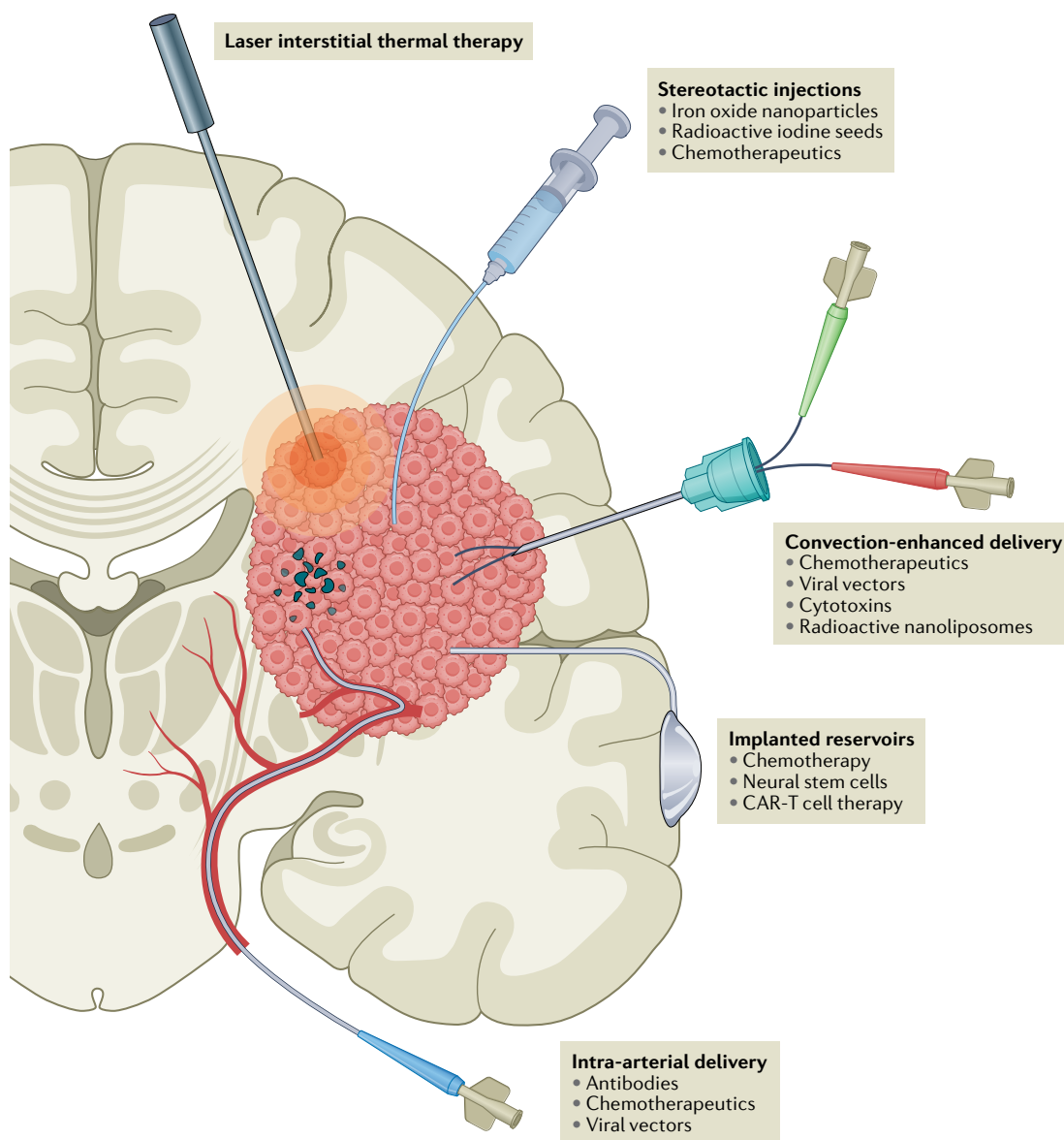


Fig. 1 | Methods of local treatment in glioblastoma. In laser interstitial thermal therapy, tumour tissue is heated with a laser probe, destroying the tissue and disrupting the blood–brain barrier (BBB), usually under MRI guidance. Various compounds can be injected via stereotactic injections directly into the tumour with the aid of neuronavigation, frequently coupled with intraoperative CT or MRI. Convection-enhanced delivery involves continuous injection of various compounds using a pressure gradient to improve distribution. Ommaya or Rickham reservoirs can be implanted, enabling intermittent injections of therapy over an extended period of time. Catheters can be placed in the tumour or resection cavity or in the cerebral ventricles. For intra-arterial delivery, catheters can be positioned directly into the feeding arteries, allowing local delivery of high-dose therapeutics. This technique can be combined with BBB disruption. CAR, chimaeric antigen receptor.

FUS can also be used for thermoablation and has been approved by the FDA for thalamotomy in patients with essential tremor³⁴. To date, only one experimental study, published in 1991, has evaluated FUS in glioblastoma³⁵. This study evaluated the use and optimal settings of a single element transducer, which was placed within the tumour through a craniotomy, in 15 patients with glioblastoma. The methods used in this study have long become obsolete, and the study offers limited clinical insight for modern glioblastoma treatment.

However, modern developments in FUS techniques, including vastly improved flexibility and precision, might uncover new possibilities for glioblastoma treatment. Ongoing trials (for example, NCT03712293 and NCT03551249) are evaluating whether BBB disruption with FUS can improve the effects of systemic chemotherapy. One study aims to combine FUS with sensitization by 5-aminolevulinic acid (5-ALA; NCT04845919), and another is exploring possible synergy with radiotherapy (NCT04988750) (Supplementary Table 1).

Photodynamic therapy

Photodynamic therapy (PDT) utilizes photosensitizing agents, which, following activation by light at a certain wavelength, generate reactive oxygen species (ROS)³⁶ (FIG. 1b). ROS interact with DNA, proteins, lipids and other macromolecules to disrupt many cellular pathways, including extensive DNA damage, leading to apoptosis of the cell³⁷. Furthermore, PDT damages vascular endothelial cells, leading to local thrombosis, vessel constriction and, ultimately, destruction of the microvasculature³⁸. Together, these effects also induce

a strong anti-glioma immune response, as shown in mouse models³⁹. Two photosensitizing agents have primarily been studied in glioblastoma: Photofrin, which is approved by the FDA for the treatment of oesophageal cancer⁴⁰, and 5-ALA, which is approved for visualization of glioblastoma cells during surgery⁴¹.

One phase III trial involving Photofrin in the treatment of glioblastoma has been published⁴². Patients who received five daily sessions of PDT via an implanted laser in the resection cavity showed improved survival compared with patients who did not receive PDT (TABLE 1). A major confounding variable is that the those who received this therapy also underwent fluorescence-guided resection, which itself improves outcomes⁴¹. Only 15% of patients in both groups received temozolomide, thereby limiting the generalizability of the findings.

A phase I trial studied intraoperative PDT, using 5-ALA, in 20 patients with recurrent glioblastoma⁴³ (TABLE 1). 5-ALA-guided resection was followed by insertion of between one and four cylindrical laser diffusers in the resection cavity. PDT was then delivered with the patient under general anaesthesia for 60 min. Postoperative MRI scans showed cytotoxic oedema along the margin of the resection cavity with contrast enhancement observed in some patients, which eventually regressed or disappeared after 4–5 months. Median PFS was 6 months, which is comparable to that achieved with standard of care in recurrent glioblastoma⁴⁴.

One of the main caveats in PDT is that the laser light has to reach cells containing the sensitizing agents. With commonly used lasers with a wavelength range

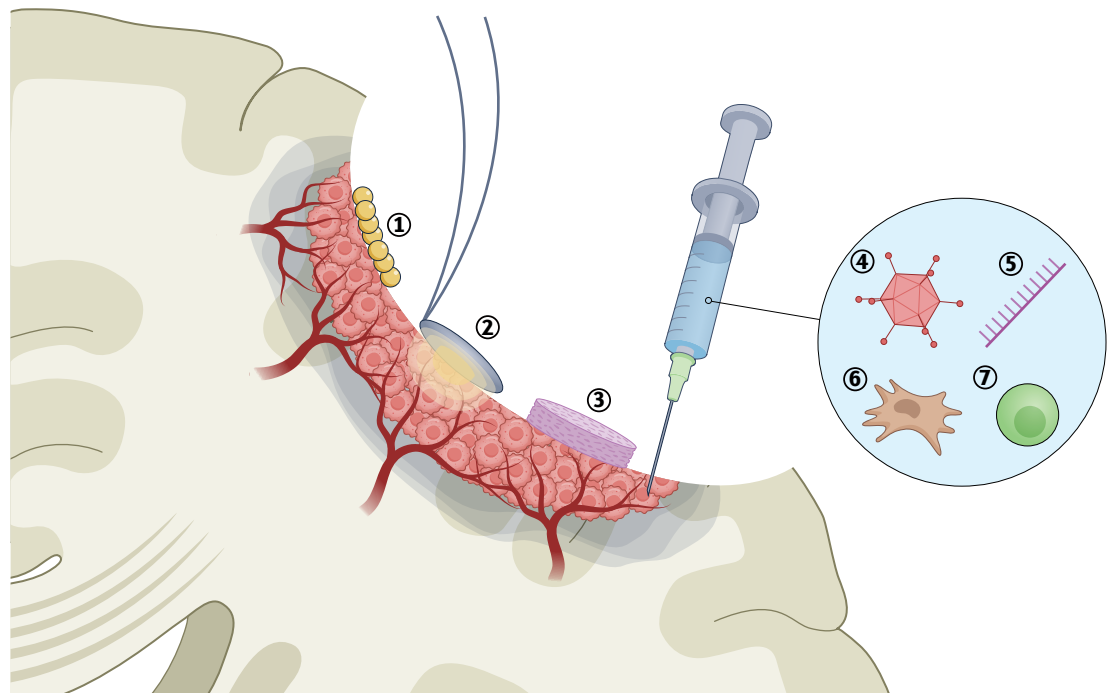


Fig. 2 | **Tumour cavity treatments for glioblastoma.** Injection of iron oxide nanoparticles (1) enables magnetic hyperthermia. In photodynamic therapy (2), photosensitizing agents are applied to the cavity and are activated by light at a specific wavelength to generate reactive oxygen species. Implantation of wafers (3) designed to release chemotherapy. Injection of viral vectors (4), immune-stimulating oligodeoxynucleotides (5), engineered neural stem cells (6) or chimeric antigen receptor (CAR) T cells (7) into the cavity wall.

Table 1 | Clinical trials in high-grade glioma: intraoperative treatment modalities

Study	Treatment	Study type	Patient cohort	Results	Adverse events (number of patients)
Localized thermotherapy					
Kamath et al. (2019) ²⁴	LITT followed by standard chemoradiotherapy	Retrospective cohort	Primary or recurrent glioblastoma (n = 54)	Median OS, 11.5 months; median PFS, 6.6 months	Cerebral oedema (3), seizures (3), hydrocephalus (1), postoperative infection leading to death (1)
Mohammadi et al. (2019) ²³	LITT followed by standard chemoradiotherapy vs chemoradiotherapy only	Retrospective, matched cohort	Primary glioblastoma (n = 48)	Median OS, 14.4 months in LITT group vs 15.8 months in controls; median PFS, 4.3 vs 5.9 months	Transient worsening of neurological deficits (6), permanent deficit (2)
Maier-Hauff et al. (2011) ²⁹	Stereotactic injection of magnetic beads + 30 Gy radiotherapy	Phase II	Primary (n = 7) or recurrent (n = 59) glioblastoma	Median OS, 13 months; median PFS, 8 months	Seizures (15), transient worsening of neurological deficits (14)
Grauer et al. (2019) ³⁰	Intracavitary superparamagnetic iron oxide particles + 60 Gy radiotherapy	Phase I	Recurrent glioblastoma (n = 6)	Median OS, 8.3 months; median PFS, 6.25 months	Inflammation and oedema requiring treatment (6), removal of beads owing to mass effect (4)
PDT					
Schipmann et al. (2020) ⁴³	Peroperative PDT of resection cavity in 5-aminolevulinic acid-treated patients	Phase I	Recurrent high-grade glioma (n = 20)	Median OS not reached, 75% alive after 6 months; median PFS, 6.0 months; 75% of tumours recurred at site of PDT	Surgical site infection (1)
Eljamel et al. (2008) ⁴²	Fluorescent-guided resection followed by five sessions of PDT + radiotherapy vs non-fluorescent-guided resection + radiotherapy	Phase III	Primary glioblastoma (n = 27)	Median OS, 12.2 months in PDT group vs 5.6 months in controls; median PFS, 8.6 vs 4.8 months	Deep vein thrombosis (3)

LITT, laser interstitial thermal therapy; OS, overall survival; PDT, photodynamic therapy; PFS, progression-free survival.

of 630–690 nm, penetration is rarely beyond 5 mm in most tissues⁴⁵. The effects of PDT might reach somewhat further, with MRI showing an average penetration of 9.1 mm (REF.⁴³) and post-mortem histopathological analysis indicating penetration up to 12.7 mm (REF.⁴⁶). However, deeper-lying malignant cells will still be entirely unaffected. Furthermore, one study showed that 75% of tumour recurrences occurred within the area of PDT⁴³, casting doubt on the long-term effects even in the resection cavity itself. Nevertheless, in view of the clinical availability of 5-ALA and the low-risk nature of this therapy, further studies into its applicability for glioblastoma are warranted⁴⁷. Preliminary data from the phase I INDYGO study have shown safety and feasibility of 5-ALA-based PDT in primary glioblastoma⁴⁷. Two other trials will provide further data on stereotactic PDT in primary (NCT03897491) and recurrent (NCT04469699) glioblastoma (Supplementary Table 1).

Local delivery of chemotherapy Convection-enhanced delivery

Convection-enhanced delivery (CED) (FIG. 1c) is a delivery method rather than a therapy itself. Compounds injected directly into brain parenchyma or tumour tissue usually diffuse poorly; for example, it can take up to 3 days for an immunoglobulin to diffuse 1 mm from an injection site in the brain⁴⁸. CED establishes a positive pressure gradient and can be left in situ for an extended period of time. This approach improves spatial distribution, with lower concentrations of compounds being necessary to treat a similar area. CED occurs independently of the molecular weight or diffusivity of an agent⁴⁹.

Although CED of chemotherapy has been successful in the laboratory, translation to the clinic has proved difficult, and several challenges have been identified that need to be addressed to improve the use of CED in patients⁴⁹. Accurate cannula placement is challenging, with one major trial (PRECISE, discussed in detail below) noting that less than 70% of cannulas were positioned in accordance with protocol guidelines⁵⁰. Post hoc analysis suggested that correct catheter placement correlated with an increase in survival. Although the neurosurgeons in this study were trained and a steering committee monitored catheter placement, the learning curve remained steep. CED trials should ideally be restricted to centres with adequate experience in this procedure.

Distribution of the infusate through the tumour is another important factor. Glioblastoma is heterogeneous in nature, with varying degrees of necrosis, angiogenesis and metabolism rates even within the same tumour, leading to wide-ranging rates of clearance^{51,52}. Methods are being developed to monitor the infusate and visualize the spread through the tumour and beyond. Gadolinium-based compounds have been used in animal models^{53,54}, and various case reports^{55,56} indicate that this approach is feasible and safe. In a phase I dose-escalation trial, nimustine hydrochloride (ACNU) was delivered with 1 mM of gadolinium-tetraazacyclododecanetetraacetic acid (Gd-DOTA) via CED to patients with recurrent diffuse intrinsic pontine glioma (DIPG) or recurrent glioblastoma located in the brainstem⁵⁷ (TABLE 2). The volume of infusion correlated closely with the signal on MRI but

Table 2 | Clinical trials in high-grade glioma: local delivery of chemotherapeutic agents

Study	Treatment	Study type	Patient cohort	Results	Adverse events (number of patients)
Convection-enhanced delivery					
Saito et al. (2020) ⁵⁷	Single dose of ACNU via convection-enhanced delivery	Phase I, dose-escalation	Diffuse intrinsic pontine glioma or recurrent brainstem glioblastoma (n = 16)	Decrease in tumour volume in four of six patients at highest dose	Transient worsening of neurological deficits (11)
Implanted and injected modalities					
Westphal et al. (2003) ⁶⁰	Implanted biodegradable carmustine or placebo wafers after surgery, followed by radiotherapy	Phase III	Primary high-grade glioma or metastasis (n = 240)	Median OS (glioblastoma only), 13.5 months in carmustine group vs 11.4 months in controls; median PFS (glioblastoma only), 5.9 months in both groups	Increased occurrence of intracranial hypertension and cerebrospinal fluid leaks
De Bonis et al. (2012) ⁶²	Carmustine wafers in resection cavity + temozolomide and radiotherapy vs temozolomide + radiotherapy only	Retrospective analysis	Primary or recurrent glioblastoma (n = 165)	Median OS (primary glioblastoma), 14 months in carmustine group vs 11 months in controls; median OS (recurrent glioblastoma), 8 months vs 9 months	Increased adverse events in patients who received eight wafers
Yang et al. (2018) ⁶⁴	ACNU into resection cavity via Ommaya reservoir with transient BBB disruption vs standard chemoradiotherapy only	Phase II	Primary glioblastoma (n = 71)	Median OS, 18.5 months in ACNU group vs 16.0 months in controls; median PFS, 8.8 vs 7.0 months	No increase in adverse events
Intra-arterial delivery					
Boockvar et al. (2011) ⁶⁸	Single dose of intra-arterial bevacizumab with osmotic BBB disruption	Phase I	Recurrent glioblastoma (n = 30)	Radiographic reduction in tumour size in most patients, most pronounced in patients who had not previously received bevacizumab (reduction in tumour enhancement on MRI, 34.7% vs 15.2% in previously treated group)	Seizures (2), perioperative rupture of right anterior cerebral artery causing subarachnoid haemorrhage and left hemiparesis (1)
Chakraborty et al. (2016) ⁷¹	Single dose of intra-arterial cetuximab with osmotic BBB disruption	Phase I	Recurrent glioblastoma (n = 15)	Well tolerated to 250 mg/m ²	Anaphylaxis (1), seizure (1), cerebral oedema with seizure (1)
Fortin et al. (2014) ⁷²	Repeated intracarotid carboplatin injection every 4 weeks	Phase II	Recurrent glioblastoma (n = 51)	3 complete responses, 22 partial responses, 14 with stable disease	Transient carotid spasms (3)

ACNU, nimustine hydrochloride; BBB, blood–brain barrier; OS, overall survival; PFS, progression-free survival.

stopped increasing after several hours despite continued administration of Gd-DOTA. The authors concluded that the retention of Gd-DOTA following local infusion was insufficient, thereby hindering precise monitoring for longer periods. Outcomes were variable, with four of six patients who received the highest doses of ACNU showing regression of tumour volume and one showing complete remission. Transient worsening of symptoms occurred in 11 of 16 patients and persisted in three of these individuals.

As glioblastomas are highly infiltrative, compounds need not only penetrate deeply into the tissue but also distinguish between malignant and normal tissue to avoid serious adverse effects. Therefore, many trials are studying CED of tumour-targeting compounds, such as cytokines, viruses, gene therapies and antibodies. These approaches are discussed in more detail below.

Advances in CED are ongoing, with continual improvements in cannula design, treatment plans and modelling of optimal delivery^{49,58,59}. Several phase I trials to study and improve CED — including image-guided approaches — for the delivery of agents such as irinotecan liposomes (NCT03086616 and NCT02022644)

and MTX110 (NCT03566199) in people with DIPG or glioblastoma have recently been completed or are currently recruiting patients (Supplementary Table 2), and the data are awaited.

Implanted and injected modalities

Biodegradable carmustine wafers were developed to deliver high-dose chemotherapy within the resection cavity (FIG. 2c). One randomized controlled trial in patients with primary glioblastoma who were receiving surgery and radiotherapy indicated that these wafers increased median survival from 11.4 months to 13.5 months⁶⁰ (TABLE 2). The diagnosis was only made after wafer implantation, so the study also included patients with other tumour types such as oligodendroglioma and brain metastases. As the power analysis did not take this into account, the results for patients with glioblastoma were not adequately powered to draw definitive conclusions.

A meta-analysis of data collected after the Stupp protocol was introduced showed that carmustine wafers have limited additional benefits in terms of OS and substantially increased the risk of adverse events in patients

receiving temozolomide⁶¹ (TABLE 2). Of note, in one major retrospective analysis that compared carmustine wafers plus the Stupp protocol with the Stupp protocol alone in 165 patients with primary or recurrent glioblastoma, implantation of eight carmustine wafers (27 patients) — but not seven wafers or fewer (20 patients) — was associated with an increased risk of adverse events⁶². This study noted a trend towards prolonged OS in patients with primary glioblastoma who received wafers, but it was not sufficiently powered to draw definitive conclusions. Nevertheless, these findings raise the possibility that an optimal dose, with acceptable levels of toxicity, can be found for carmustine wafers in combination with the Stupp protocol. One study (NCT03234595) is currently evaluating wafer-mediated delivery of *n*-butylidenephthalide, which showed promise in pre-clinical models⁶³, in patients with recurrent glioblastoma (Supplementary Table 2).

Placement of an Ommaya or Rickham reservoir connected to the resection cavity or cerebral ventricles enables delivery of high-dose chemotherapy to the tumour over extended time periods (FIG. 1d). The reservoir is implanted under the skin and can be accessed intermittently, allowing more flexibility for the patient and clinician during the course of treatment. One study delivered ACNU into the resection cavity via an Ommaya reservoir during temozolomide treatment and radiotherapy in 71 patients with glioblastoma⁶⁴ (TABLE 2). Each injection was combined with transient BBB disruption with mannitol and dexamethasone. No serious adverse events were noted; however, improvement in OS (median 18.5 months compared with 16.0 months for standard therapy) and PFS (8.8 months versus 7.0 months) was minimal⁶⁴. Furthermore, the interpretation of the results was limited by several factors: the study was non-randomized in that patients were allowed to choose the treatment and had to be able to afford the extra treatment; imaging data were not available; and the ACNU group also received mannitol and dexamethasone to disrupt the BBB. A more robust randomized trial might shed more light on the efficacy of this approach.

Generally, wafers and reservoirs can enable long-term delivery of compounds. The current literature is critical of implantable carmustine wafers, but adjustments of compounds, dose and implantation techniques might improve their efficacy and safety⁶¹. CED seems to be more effective at diffusing compounds directly into tumour tissue but is also more invasive. Implanted reservoirs might serve a specific function in the treatment of the resection cavity or delivery to the cerebral ventricles over extended periods of time but have yet to find a defined role in the treatment of glioblastoma.

Intra-arterial delivery

Intra-arterial delivery of chemotherapeutics (FIG. 1e) was seen as a promising treatment in the early days of glioblastoma treatment when few other modalities were available⁶⁵. With the advent of temozolomide, radiotherapy and improved neurosurgical techniques, interest in intra-arterial delivery diminished at the end of the 1990s owing to concerns over neurotoxicity and other adverse events. However, recent improvements in angiographic

techniques have led to renewed interest, as reviewed in 2020 by D'Amico et al.⁶⁶. In this section, we briefly highlight the most notable developments.

High dosages of therapeutic drugs can be administered directly to the tumour bed via intra-arterial catheters. Usually, this technique is combined with transient BBB disruption to maximize passage of the compound across the BBB. This disruption can be achieved with drugs such as mannitol, or with FUS⁶⁷. Nuances and considerations regarding BBB disruption are beyond the scope this Review and can be found elsewhere⁶⁷. Several phase I trials have studied intra-arterial administration of bevacizumab in patients with glioblastoma, and have shown an acceptable safety profile with variable responses to treatment^{68–70} (TABLE 2). Various phase I and II trials for primary and recurrent glioblastoma are currently underway (for example, NCT01269853, NCT02285959 and NCT01811498), but no phase III trials are planned at present (Supplementary Table 2). Intra-arterial delivery of cetuximab, an epidermal growth factor receptor inhibitor, is also under investigation (NCT02800486 and NCT02861898) after a phase I trial showed that delivery is well tolerated, even at high doses⁷¹ (TABLE 2). With regard to chemotherapeutics, intra-arterial delivery of carboplatin without BBB disruption seems to be safe in individuals with recurrent glioblastoma, with minor haematological adverse effects and no neurological complications being observed⁷². Of 51 patients in this trial, 25 showed a complete or partial response. A phase II trial (NCT03672721) is now underway (Supplementary Table 2).

Overall, selective intra-arterial delivery, combined with BBB disruption, shows considerable promise, either as salvage therapy in inoperable patients or in combination with current standard of care. The experience gained from other intra-arterial cerebral treatments, such as coiling and thrombectomy, has improved the availability and safety of these techniques, and many compounds are available to be tested. Drug selection is important, and factors such as local and systemic toxicity, ease of uptake on first pass and tissue retention must be carefully considered⁶⁶. Furthermore, hydrodynamic factors differ between tumours, and even within the same tumour, which can influence the delivery and, thus, the efficacy of compounds^{73–75}. Tumours with low blood flow are thought to respond better to intra-arterial chemotherapy⁷⁵, so techniques are being developed to transiently decrease or arrest blood flow when therapy is administered^{76,77}. The field would benefit from standardized methods and treatment protocols to allow comparison between different compounds and doses. Randomized phase III trials are urgently awaited to explore the potential of intra-arterial delivery in glioblastoma.

Localized immunotherapy

Immunotherapy is among the most studied new treatments for glioblastoma. The low immunogenicity of glioblastoma coupled with an immunosuppressive tumour microenvironment helps the tumour evade an antitumour immune response^{8,9,78}. As a result, many new systemic and local therapies have been designed

to enhance the immune system and, effectively, turn it against glioblastoma. Various reviews have discussed immunotherapy for glioblastoma at length^{79,80}; here we focus on local treatment approaches that have shown promise in clinical trials.

Viral therapy

Viral therapy can be used in various ways to combat glioblastoma. In the case of gene therapy, replication-defective viruses can function as the delivery vehicle for a transgene and hijack a cancer cell to produce the therapeutic compound. By contrast, oncolytic viruses are often replication-competent and are designed to induce cytotoxicity selectively in tumour cells⁸¹. Both of these approaches aim to trigger an immune response, thereby stimulating antitumour immunity⁸². Local delivery of the viruses increases efficiency and limits systemic spread of viral load. Many viral therapies have been

studied in patients with glioblastoma and are extensively reviewed elsewhere^{81,83}. Here, we discuss locally delivered viral therapeutics that have been tested in clinical trials since the beginning of the temozolomide era.

Gene therapy. Several viral gene therapies are in development for the treatment of glioblastoma. One of the most studied viruses is a replication-incompetent adenoviral vector known as AdvHSV-tk, which delivers the herpes simplex virus type 1 (HSV-1) thymidine kinase gene⁸⁴. When an antiviral prodrug such as ganciclovir is subsequently administered, thymidine kinase phosphorylates this prodrug, causing it to bind to DNA during double-strand break repair (FIG. 3). This process eventually disrupts mitosis and DNA repair mechanisms, leading to cell apoptosis and necrosis, and increases sensitivity to chemoradiation^{85,86}. Addition of this treatment to standard therapy has shown some promise in

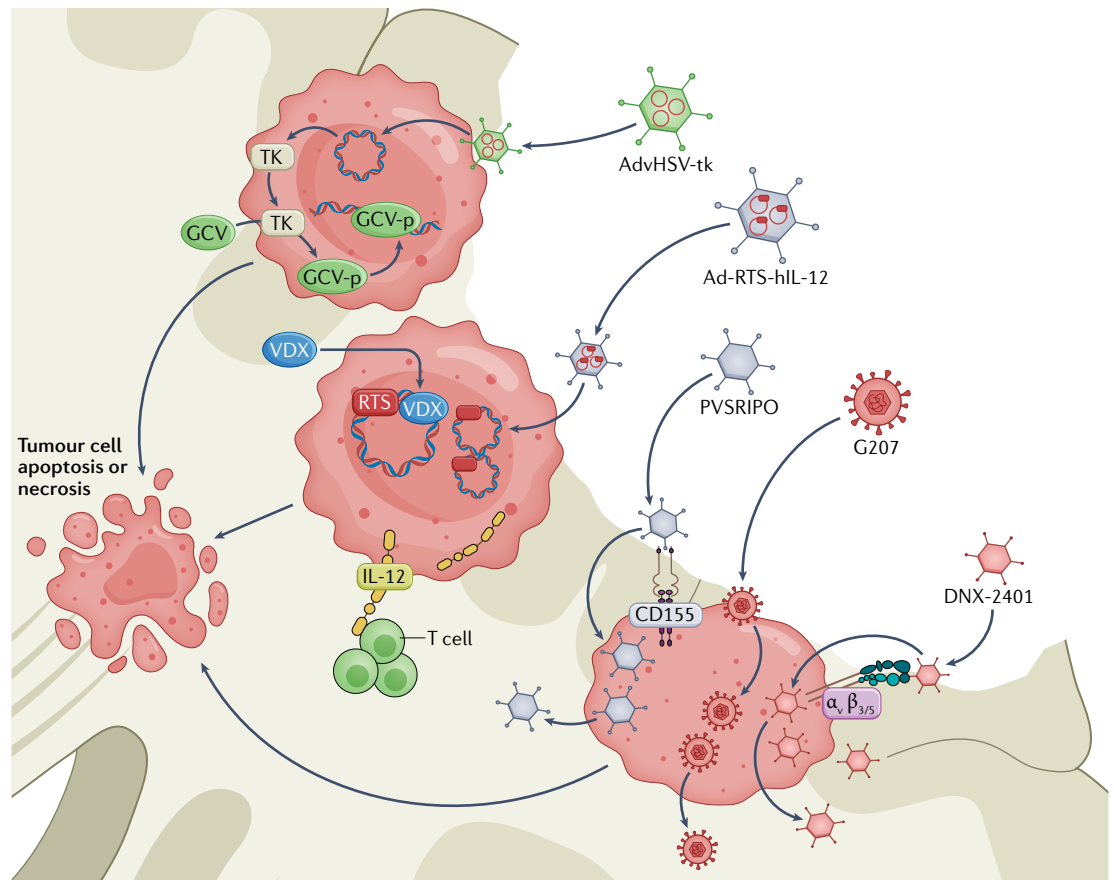


Fig. 3 | Mechanisms of local viral therapies in development for glioblastoma. AdvHSV-tk is a replication-incompetent adenoviral vector that delivers herpes simplex virus type 1 (HSV-1) thymidine kinase (TK). The transgene is introduced to the cell, and TK is produced. TK phosphorylates systemically administered ganciclovir (GCV) to generate GCV-p, which interferes with DNA repair and replication, eventually leading to tumour cell apoptosis or necrosis. Ad-RTS-hIL-12 is a replication-incompetent adenoviral vector that encodes human IL-12 preceded by a RheoSwitch Therapeutic System (RTS). The DNA construct is introduced into the cell, but can only be transcribed in the presence of veledimex (VDX). When VDX is administered systemically, IL-12 is produced. IL-12 activates T cells and generates an antitumour micro-environment. PVSRIPO is a replication-competent oncolytic polio–rhinovirus chimaera. PVSRIPO enters the cell via CD155, which is abundantly expressed in most glioblastomas. The virus then replicates in the tumour cell, leading to apoptosis and spreading of the virus. G207 is a replication-competent, oncolytic HSV-1 virus that is designed to replicate in tumour cells, causing apoptosis and viral spread. DNX-2401 is a replication-competent adenovirus. The virus enters the cell via $\alpha\beta_3$ and $\alpha\beta_5$ integrins, which are present on glioma stem cells, and cannot replicate when a functional retinoblastoma pathway is present. As this pathway is often inactivated in tumour cells, the virus can cause selective apoptosis or necrosis of these cells.

Table 3 | Clinical trials in high-grade glioma: localized immunotherapy

Study	Treatment	Study type	Patient cohort	Results	Adverse events (number of patients)
Viral therapy					
Wheeler et al. (2016) ⁸⁷	AdvHSV-tk injection in resection cavity wall + ganciclovir with standard of care	Phase II, with historical controls	Primary glioblastoma (n = 48)	3 × 10 ¹¹ particles well tolerated; median survival, 17.1 months vs 13.5 months in historical controls; median OS after gross total resection, 25.0 vs 16.9 months	Worsening of existent hemiparesis (1)
Ji et al. (2016) ⁸⁸	Repeated dosing of intra-arterial AdvHSV-tk with BBB disruption and standard of care vs standard of care	Phase II	Recurrent WHO grade III or IV glioma (n = 53)	Median OS, 10.4 months in AdvHSV-tk group vs 3.3 months in controls; median PFS, 6.8 vs 1.9 months; treatment of controls (surgery, chemotherapy or palliative care) not stated	No increased risk of adverse events
Chiocca et al. (2019) ⁸⁹	Ad-RTS-hIL-12 in resection cavity wall + systemic veledimex	Phase I	Recurrent glioblastoma (n = 31)	Maximum tolerated dose of veledimex, 20 mg; median survival, 12 months	Reversible cytokine release syndrome (10 grade 2, 6 grade 3), brain oedema (1), confusion (1), aseptic meningitis (1)
Desjardins et al. (2018) ⁹⁶	Single dose of PVSRIPO via CED	Phase I	Recurrent glioblastoma (n = 61)	Median OS, 12.5 months vs. 11.3 months in historical controls	Haemorrhage leading to hemiparesis (1), peritumoural inflammation requiring bevacizumab (32), requiring surgery (4)
Lang et al. (2018) ⁹⁸	DNX-2401 in resection cavity wall	Phase I	Recurrent glioblastoma (n = 37)	20% of patients survived >3 years, three showed >95% tumour reduction; OS, 13.0 months	Transient fever, headache and malaise (2)
Markert et al. (2014) ¹⁰²	Single stereotactic injection of G207 combined with radiotherapy	Phase I	Recurrent glioblastoma (n = 9)	Six patients showed stabilization of disease or partial response; median OS, 7.5 months; median PFS, 2.5 months	Seizures and hemiparesis (number of patients unclear)
Friedman et al. (2021) ¹⁰⁴	Single injection of G207 via CED combined with radiotherapy	Phase I	Paediatric recurrent high-grade glioma (n = 12)	Radiological and/or clinical response in 11 patients; median OS, 12.2 months	No dose-limiting adverse effects
Cytokine and antibody therapy					
Kunwar et al. (2010) ⁵⁰	Single injection of IL13-Pe38QQR via CED vs carmustine wafers	Phase III	Recurrent glioblastoma (n = 296)	Median OS, 9.1 months in IL13-Pe38QQR group vs 8.8 months in controls	Increased incidence of pulmonary embolism in IL13-Pe38QQR group (16 vs 2 patients)
Immunostimulating oligodeoxynucleotides					
Carpentier et al. (2010) ¹¹¹	Single stereotactic injection of CpG-ODN	Phase II	Recurrent glioblastoma (n = 31)	One partial response and three minor responses; median OS, 6.4 months; median PFS, 2.1 months	Transient worsening of neurological deficits (22), death owing to haemorrhage (1)
Ursu et al. (2017) ¹¹²	CpG-ODN injected into resection cavity wall followed by standard of care vs standard of care only	Phase II	Primary glioblastoma (n = 81)	Median OS, 17 months in CpG-ODN group vs 18 months in controls; median PFS, 9 months in both groups	Increased occurrence of fever and postoperative haemorrhage

BBB, blood–brain barrier; CED, convection-enhanced delivery; CpG-ODN, oligodeoxynucleotides containing unmethylated cytosine–guanine motifs; OS, overall survival; PFS, progression-free survival; PVSRIPO, recombinant non-pathogenic polio–rhinovirus chimaera.

recurrent and primary glioblastoma, and a phase III trial is currently in development^{87,88} (TABLE 3). Repeated intra-arterial delivery of AdvHSV-tk and ganciclovir has been shown to be safe and feasible and might further improve the efficacy of this treatment⁸⁸ (TABLE 3).

Another gene therapy approach uses the replication-defective adenoviral Ad-RTS-hIL-12 vector, which encodes a human *IL12* transgene under the control of a ligand-inducible expression switch⁸⁹ (FIG. 3). The vector is injected into the tumour site after resection, and

the activator ligand, veledimex, is administered orally. IL-12 is thought to have potent anticancer potential via stimulation of T cells to produce IFN γ , thereby creating a more inflammatory tumour microenvironment⁹⁰. However, systemic IL-12 administration or direct local injection of IL-12-producing lymphocytes causes severe adverse events^{91,92}. The switch method enables transcription and expression of IL-12 to be regulated, and the levels of this factor decrease rapidly when veledimex administration ceases, thereby allowing rapid correction

if adverse effects occur⁹³. A phase I dose-escalation trial demonstrated the safety of this approach, with increased inflammation and infiltration of PD1-expressing CD8⁺ T cells being noted on re-resection⁸⁹ (TABLE 3). This result, combined with improved OS after IL-12 therapy, led to the initiation of new phase I trials (NCT03636477 and NCT04006119), which are studying IL-12 viral therapy in combination with immune checkpoint inhibitors (nivolumab or cemiplimab) in an effort to further improve efficacy (Supplementary Table 3).

Toca 511 is a retroviral therapy that is designed to induce expression of cytosine deaminase in tumour cells via a retroviral replicating vector. This enzyme converts the prodrug 5-fluorocytosine to 5-fluorouracil, a potent chemotherapeutic that has shown efficacy against glioma⁹⁴. A phase I trial showed promising responses in 45 patients with recurrent glioblastoma⁹⁵, but a subsequent phase III trial (NCT02414165) was terminated by the company after failing to show any improvements over standard of care.

Oncolytic therapy. PVSRIPO is a recombinant, replication-competent oncolytic polio-rhinovirus chimaera that has been tested in recurrent glioblastoma⁹⁶. Infection with PVSRIPO requires expression of CD155, which is abundant on glioblastoma and, to a lesser extent, on antigen-presenting cells (FIG. 3). PVSRIPO infection of the tumour cells halts protein synthesis and induces oncolysis, whereas infection of non-tumour antigen-presenting cells leads to interferon-dominant activation of the tumour microenvironment and an enhanced T cell response⁹⁷. After patients received PVSRIPO via CED, a strong inflammatory response was observed, which necessitated surgery in 4 of 61 individuals⁹⁶ (TABLE 3). Later in the study, the addition of lomustine seemed to be beneficial when treating recurrence: about one-third of patients who also received this drug showed radiographic signs of cystic tumour degradation and a rapid decline in tumour volume. OS was not improved compared with historical controls. A phase II trial in patients with recurrent glioblastoma is now underway (NCT02986178), and the use of PVSRIPO is also being explored in paediatric patients with recurrent high-grade glioma (NCT03043391) (Supplementary Table 3).

Another replication-competent oncolytic adenovirus is DNX-2401 (REF.⁹⁸). This vector is designed to enter cells that express high levels of $\alpha v\beta 3$ and $\alpha v\beta 5$ integrins, such as glioma stem cells, but it cannot replicate when a functional retinoblastoma (Rb) pathway is present. The Rb pathway regulates the G1 checkpoint of the cell cycle, and this pathway is frequently inactivated in cancers, including gliomas^{99,100}. Consequently, replication of DNX-2401 is limited to tumour cells¹⁰⁰ (FIG. 3). DNX-2401 kills tumour cells by direct oncolysis, which also induces an inflammatory response. A phase I trial demonstrated that stereotactic injection of DNX-2401 into the tumour or the resection cavity wall is safe⁹⁸ (TABLE 3). Tumour reduction was observed in 72% of patients, with a median OS of 13.0 months. Three patients showed more than 95% tumour reduction after injection and were alive 3 years after the start of treatment. Data are currently awaited from a recently

completed phase II trial, combining DNX-2401 with the anti-PD1 monoclonal antibody pembrolizumab (NCT02798406). The same group is also investigating intra-arterial injection of mesenchymal stem cells (MSCs) loaded with DNX-2401 before and after surgery in patients with recurrent glioblastoma (NCT03896568) (Supplementary Table 3).

G207 is a replication-competent oncolytic HSV-1 vector. Deletion of the diploid $\gamma_1 34.5$ neurovirulence gene and inactivation of viral ribonucleotide reductase via insertion of *Escherichia coli* lacZ prevents infection of normal cells while allowing replication in tumour cells¹⁰¹ (FIG. 3). A phase I trial in patients with recurrent glioblastoma showed that when administered into the resection bed, G207 is safe, can be combined with radiotherapy and induces a response in the majority of patients¹⁰² (TABLE 3). As xenograft studies indicated that paediatric glial tumours have a markedly increased sensitivity to G207, possibly owing to increased expression of CD111 (nectin 1)¹⁰³, a phase I trial evaluated the safety of this vector in a cohort of paediatric patients with high-grade glioma¹⁰⁴ (TABLE 3). No serious adverse events were found, and a response was observed in 11 of 12 patients. Median survival was 12.2 months, which is remarkable for paediatric patients with recurrent high-grade glioma. Combination with radiotherapy was well tolerated and this approach will be studied further in an upcoming phase II trial (NCT04482933) (Supplementary Table 3).

Summary. Viral therapy in glioblastoma has generated considerable interest and excitement. Some patients have shown remarkable responses to these therapies, with long-term survivors in several studies^{96,98,104}. However, not all patients benefit from these treatments, and further study and analysis of the factors that influence the response is warranted⁸¹ (BOX 1). One potential confounding factor is that most of the long-term responders seem to have favourable prognostic factors such as small tumour size, young age, isocitrate dehydrogenase 1 (*IDH1*) and *IDH2* mutations, 6-O-methylguanine–DNA methyltransferase (*MGMT*) promoter methylation and good performance status⁸¹. These observations point to a general problem when studying recurrent glioblastoma: the patient population is usually heterogeneous with regard to age, performance status, molecular subtype, previous therapy and dexamethasone use. In addition, the patients who are selected for these experimental trials are likely to be well-motivated individuals with high socioeconomic status — factors that contribute to improved outcomes in general¹⁰⁵.

The literature on viral therapies for glioblastoma currently consists largely of phase I and II trials¹⁰⁶, and phase III trials in large patient cohorts will be essential to determine the true value of these therapies. At present, however, no such trials are registered at ClinicalTrials.gov (Supplementary Table 3).

Cytokine therapy

Systemically administered cytokines can induce an immune response against cancer but also carry a large risk of toxicity and adverse events⁹². Consequently, strategies are being developed to localize the release of

Box 1 | Selection bias in early-phase clinical trials

This Review discusses many phase I and II trials of local therapy for glioblastoma that demonstrate some form of treatment response or efficacy. However, translation of these promising results into successful randomized phase III trials has so far been lacking. Several factors could have contributed to this apparent discrepancy.

Patients selected for phase I and II trials are usually a subset of individuals with good performance status, no comorbidities, relatively young age and high motivation to undergo further treatment. A Swedish study showed that only a minority of patients with glioblastoma meet the current study inclusion criteria, and this group already has significantly improved median overall survival — 16.4 months compared with 7.7 months for patients who do not meet the criteria — regardless of whether additional therapy is administered¹¹⁸. Comparing these patients with historical or non-participating controls will, therefore, bias the data towards favourable outcomes for the study cohort.

Similarly, in several phase I and II trials, some patients showed remarkable long-term survival after treatment⁸¹. However, in the Swedish study, 8.6% of the patients who were deemed eligible for study inclusion at diagnosis had an overall survival of more than 5 years¹¹⁸. A retrospective analysis of patients with glioblastoma in Australia also noted that participation in a clinical trial was associated with improved survival, regardless of treatment allocation and independent of performance status, age and tumour location¹¹⁷.

Patients might benefit from participating in clinical trials by having access to better care, including more frequent check-ups, imaging and physician contact. Consequently, disease progression and complications are more closely monitored and potentially treated earlier compared with patients who are not participating in clinical trials. Factors such as socioeconomic status and race could also influence trial participation and survival outcomes, although precise data are currently lacking^{105,148}. In addition, phase I and II studies in recurrent glioblastoma often include patients with a wide range of disease progression, tumour size, previous treatments and dexamethasone usage, all of which can influence survival and response to treatment^{149,150}. Therefore, drawing general conclusions from this patient group is complex and should be done with the utmost caution.

To improve generalizability and applicability, large, multicentre, randomized clinical trials are necessary. Given the substantial financial and regulatory hurdles, however, this approach is not feasible in the early stages of treatment development. To enable the generalizability of smaller trials to be assessed, these trials must include extensive data on patient characteristics, including not only tumour size, location, steroid use and previous treatments, but also socioeconomic background, race and education. Immune and genetic profiling of tumours is becoming more accessible and should be included in the patient data and outcome analyses wherever possible.

cytokines to induce local inflammation while avoiding a systemic response.

The PRECISE trial utilized expression of IL-13 by glioblastoma cells to facilitate entry of exotoxin A, a cytotoxin derived from *Pseudomonas aeruginosa*⁵⁰. By fusing IL-13 to this exotoxin, the researchers created a recombinant chimaeric cytotoxin known as IL13-PE38QQR, which inhibits protein synthesis and induces apoptosis¹⁰⁷. A randomized phase III trial was performed in 296 patients with recurrent glioblastoma⁵⁰. After gross total resection of the tumour, the participants were randomly assigned to receive either IL13-PE38QQR via CED or implantation of carmustine wafers. No difference in OS was found, but the incidence of pulmonary embolism was significantly higher in the those treated with IL13-PE38QQR, possibly owing to prolonged hospital stay and additional surgery (TABLE 3). As discussed previously, appropriate placement of the catheters was challenging, with less than 70% of catheters adequately positioned. Despite efforts to optimize delivery of IL13-PE38QQR, these results were disappointing and no new trials with this cytotoxin are currently planned.

To date, local injection of cytokines has shown limited promise. The rise of gene therapies such as Ad-RTS-hIL-12 with veledimex⁸⁹, which can regulate delivery of cytokines over time without the need for CED or repeated surgery, might limit the role of direct injection of cytokines into the tumour. However, new gene therapies require careful design and testing, with a long developmental trajectory to reach the clinic. Direct injection could serve as a first-line method to evaluate the functionality of the cytokine, before developing more suitable methods of delivery. Currently, CED of various cytokines and antibodies is being tested in phase I trials, including ¹²⁴I-omburtamab (NCT01502917), anti-CD26 (NCT04608812), anti-CD40 (NCT04547777) and bone morphogenetic protein 4 (NCT02869243) (Supplementary Table 3).

Immunostimulatory oligodeoxynucleotides

To enhance the immune response to tumour cells, immunostimulatory oligodeoxynucleotides containing unmethylated cytosine–guanosine motifs (CpG-ODN) have been developed to activate Toll-like receptor 9 (TLR9)¹⁰⁸. As TLR9 is mainly expressed by antigen-presenting cells, such as plasmacytoid dendritic cells and microglia¹⁰⁹, CpG-ODNs injected into glioblastoma are hypothesized to increase antigen presentation and, consequently, improve the immune response. Promising responses to CpG-ODNs were reported in mice¹¹⁰. However, two phase II trials in which these CpG-ODNs were injected into the tumour cavity wall after resection of primary or recurrent glioblastoma failed to show improvements in outcomes when combined with standard chemoradiotherapy^{111,112} (TABLE 3). A possible explanation is that antigens presented by microglia or dendritic cells fail to induce an immune response if these antigens are not recognized by T cells as foreign. One of the hallmarks of glioblastoma is immunosuppression, with limited T cell infiltration into the tumour¹¹³. This immunosuppression is further aggravated by the use of dexamethasone, and in the phase II trial in recurrent glioblastoma, only four of 34 patients were not receiving this drug¹¹¹. Minimization of steroid use and/or combination with immune checkpoint inhibition might be beneficial for these therapies. No trials are currently studying CpG-ODN in glioblastoma.

Localized radiotherapy

Radiotherapy has been a cornerstone of glioblastoma treatment for many years. Improvements are continually being made to minimize harm to healthy tissue while maximizing the dose administered to the tumour area. The current standard of care involved stereotactic radiotherapy with a total dose of 60 Gy, delivered in 30 fractions of 2 Gy over 6 weeks¹¹⁴. Radiotherapy targets the surgical cavity, often including the margin where peritumoural oedema is seen on fluid-attenuated inversion recovery MRI sequences. Over 80% of glioblastoma recurrences occur within these radiotherapy fields¹¹. In an effort to increase the dose received by the tumour bed while minimizing damage to surrounding tissue, various forms of brachytherapy — a type of radiotherapy in which a radiation source is implanted in or

near the tumour — have been investigated, with varying degrees of success¹¹⁵. In this section, we discuss the latest developments.

A 2019 study based on the Surveillance, Epidemiology and End Results database concluded that OS is improved in patients who have received some form of brachytherapy for glioblastoma¹¹⁶. The study included a total of 60,456 patients who were diagnosed with primary glioblastoma between 1975 and 2015, 362 of whom received brachytherapy. A multivariate Cox regression analysis including age, tumour size, tumour location, extent of resection and chemotherapy and/or radiotherapy treatment showed brachytherapy to be an independent predictor of improved outcome (as were all the other included variables). However, this study had multiple limitations. Most patients were treated before the introduction of the Stupp protocol, patients enrolled in clinical studies were likely to have an improved outcome regardless of treatment group allocation^{117,118}, and no data were available regarding *IDH* or *MGMT* aberrations in these groups. Therefore, no firm conclusions can be drawn from these data.

Two studies evaluated low dose-rate brachytherapy involving stereotactic implantation of ¹²⁵I seeds in patients with inoperable (predominantly recurrent) glioblastoma^{119,120} (TABLE 4). These studies demonstrated the safety of the procedure, with manageable adverse effects related to postoperative oedema. However, no evidence of improvements in patient outcomes was found in either study. Schwartz et al.¹¹⁹ observed that all instances of tumour progression occurred in the vicinity of the treated area, casting further doubt on the usefulness of low-dose brachytherapy in glioblastoma. A clinical trial is currently evaluating the dose, safety and efficacy of ¹⁸⁶Re nanoliposomes delivered by CED in recurrent glioblastoma (NCT01906385). These nanoliposomes have shown promise in preclinical models¹²¹, but whether the findings will translate to a clinical response remains to be seen.

Another technique in development is intraoperative radiotherapy (IORT), which has shown promise in breast and colon cancer¹²². A retrospective analysis gathered outcome and toxicity data from 51 patients with primary glioblastoma who were treated with IORT in addition

to the Stupp protocol¹²³ (TABLE 4). Most patients received 10 Gy IORT via a spherical applicator in the resection cavity. Toxicities were limited to radiation necrosis in 13 patients, and outcomes were positive (TABLE 4). Of special interest is the finding that tumour progression initiated locally in only 35.5% of patients, compared with the usual 80% in glioblastoma¹¹. A large multicentre phase III trial is attempting to recruit 314 patients to evaluate whether IORT as an addition to first-line treatment can improve outcomes in glioblastoma (NCT02685605) (Supplementary Table 4).

Engineered stem cells and T cells

MSCs and neural stem cells (NSCs) are known to migrate towards damaged tissue and tumours, are able to release bioactive molecules, and can induce positive immunomodulatory effects¹²⁴. Several studies in mice have shown the potential of modified MSCs and NSCs, injected either intravenously or intracranially, to migrate towards glial tumours and deliver chemotherapy, such as paclitaxel¹²⁵, or convert a prodrug into a toxic compound¹²⁴. The latter technique was studied in a phase I trial in patients with recurrent glioblastoma¹²⁶ (TABLE 5). A human NSC line, HB1.F3, was retrovirally transduced to express cytosine deaminase, which converts 5-fluorocytosine, a non-toxic compound that crosses the BBB, to 5-fluorouracil, a cytotoxic agent. The NSCs were injected into the wall of the resection cavity or into the tumour tissue that remained after resection, and 5-fluorocytosine was administered orally. Three different doses of NSCs were tested, and the six patients who received the highest dose (5×10^7 NSCs) had a median OS of 15.4 months, compared with only 2.9 months in patients who received lower doses. Post-mortem pathological assessment in two patients found injected NSCs in tumour tissue, but also showed migration of NSCs to sites distant from the tumour, crossing the corpus callosum in one patient. Given the deep infiltration of glioblastoma cells throughout the brain, deep spread of NSCs is an important and encouraging finding. One theoretical limitation is the possibility for NSCs to become tumorigenic, as they are immortalized through expression of *MYC*¹²⁷, but this phenomenon was not observed in the present study¹²⁶.

Table 4 | Clinical trials in high-grade glioma: localized radiotherapy

Study	Treatment	Study type	Patient cohort	Results	Adverse events (number of patients)
Schwartz et al. (2015) ¹¹⁹	Stereotactic implantation of ¹²⁵ I beads	Retrospective cohort	Recurrent high-grade glioma (n = 68)	Median OS, 41.8 months; median PFS, 8.3 months; treatment failure observed in 57 patients	Surgical revision of beads (1), oedema requiring steroids and bevacizumab (6)
Kickingereder et al. (2014) ¹²⁰	Stereotactic implantation of ¹²⁵ I beads vs standard of care only	Retrospective cohort	Inoperable primary or recurrent glioblastoma (n = 201)	Median OS, 11.1 months; median PFS, 6.2 months	Transient oedema treated with corticosteroids (7), persistent neurological deficits owing to oedema (3), cyst requiring stereotactic evacuation (1), abscess requiring stereotactic drainage (1)
Sarria et al. (2020) ¹²³	Intraoperative radiotherapy + standard of care	Retrospective cohort	Primary glioblastoma (n = 51)	Median OS, 18.0 months; median PFS, 11.4 months	Radiation necrosis, no intervention required (12)

OS, overall survival; PFS, progression-free survival.

Table 5 | Clinical trials in high-grade glioma: neural stem cell therapy

Study	Treatment	Study type	Patient cohort	Results	Adverse events (number of patients)
Portnow et al. (2017) ¹²⁶	Neural stem cells expressing cytosine deaminase into resection cavity wall	Phase I	Recurrent high-grade glioma (n = 15)	Median OS, 8.4 months; median PFS, 1.0 month; higher dose correlated with longer survival	Death owing to haemorrhage (1), grade 3 liver toxicity necessitating termination of treatment (1)
Fares et al. (2021) ¹²⁸	Neural stem cells delivering oncolytic adenovirus into resection cavity wall	Phase I	Primary high-grade glioma (n = 12)	Median OS, 18.4 months; median PFS, 9.1 months	Meningitis owing to injection into cerebral ventricle (1)

OS, overall survival, PFS, progression-free survival.

Furthermore, not all patients are able to receive this therapy as some express antibodies against class I or II HLA (3 of 18 in this study). A new study is exploring the combination of carboxylesterase-expressing allogeneic NSCs with irinotecan hydrochloride in patients with recurrent glioblastoma (NCT02192359) (Supplementary Table 5).

An interesting pilot study demonstrated the possibility of delivering an oncolytic adenovirus (CRAd-S-pk7) via NSCs in patients with primary glioblastoma¹²⁸ (TABLE 5). This method combines the tumour-trophic characteristics of NSCs with the sustained oncolytic capabilities of a replication-competent virus, and has produced positive results in animal models¹²⁹. Injection of these NSCs into the cavity wall after resection induced an influx in CD8⁺ T cells at the tumour site, and patients who received the treatment had a median OS of 18.4 months. No traces of either NSCs or adenoviral vectors were found on re-resection or autopsy 4–24 months after injection. A phase II trial (NCT03072134) has recently been completed, with results expected soon (Supplementary Table 5).

Chimaeric antigen receptor (CAR) T cell therapy has shown impressive results in B cell malignancies and is currently being developed for various solid cancers. A complete overview of the current state of CAR T cell therapy in glioblastoma is provided elsewhere¹³⁰. The potential to deliver these T cells locally to the tumour has gained attention in recent years. Currently, a phase I study is recruiting patients to receive CAR T cells via a Rickham catheter (NCT02208362) (Supplementary Table 5). In this study, CAR T cells targeting IL-13R α 2 are generated through lentiviral transduction of enriched central memory T cells and are injected into the tumour cavity on a weekly basis. One patient from this study, who had recurrent glioblastoma and multiple lesions in the brain and spinal cord, showed a remarkable response, although the lesions recurred after 8 months¹³¹. Many studies are currently testing various forms of CAR T cell therapy, some in combination with checkpoint inhibition (NCT04003649) or temozolomide (NCT04165941) (Supplementary Table 5).

Engineered stem cells and T cells are still in the early stages of development for the treatment of glioblastoma. The tumour-homing abilities of NSCs and T cells are highly relevant in glioblastoma, which has often infiltrated deep into the brain by the time of diagnosis^{132–134}. Local delivery ensures that most cells arrive at the area with the highest number of tumour cells, but this approach might not be amenable to repeated dosing. The presence of NSCs months after administration was noted

in one study¹²⁶ but not in another¹²⁸. Some questions regarding malignant transformation of NSCs remain and the dynamics and life cycle of NSCs requires further study, but given the aggressive nature of glioblastoma, long-term adverse effects might be less relevant than in some other cancers. A major factor that complicates CAR T cell therapy in glioblastoma is that the T cells are modified to attack tumour cells expressing specific antigens. However, glioblastoma is notoriously heterogeneous and expression profiles can change drastically in response to treatment, which might limit long-term efficacy^{135,136}. The immunosuppressive tumour microenvironment and the frequently observed T cell exhaustion in glioblastoma provide additional challenges for this therapy^{113,137}. Further research is needed in the clinical and preclinical settings to address these issues. Furthermore, CAR T cell therapy is currently highly labour-intensive for clinicians and financially prohibitive for many patients. Although this field is developing rapidly, phase III trials have not yet been planned (Supplementary Table 5).

Conclusions and future prospects

In glioblastoma, most recurrences occur in — or close to — the resection cavity¹¹. Directing therapy to the tumour cavity might, therefore, improve treatment efficacy. Local therapies for glioblastoma are an attractive prospect; however, most novel approaches are still in the developmental phase. Local gene therapy and oncolytic viral therapies show promise and are awaiting further phase II–III trials. A major strength of local therapy lies in minimizing systemic adverse effects and interactions, thereby allowing combinatorial approaches with systemic therapies. Many current clinical trials are evaluating combinations of local and systemic therapy (Supplementary Tables 1–5). Monitoring of systemic levels of locally administered agents has shown that crossing of the BBB is usually minimal^{104,126}, and most trials indicate that systemic adverse effects rarely occur. Therefore, combining local and systemic therapy could be safe, at least in certain cases; however, more studies are necessary.

Although treatment of the surgical cavity might enhance local control of the tumour, it does not attack deeply infiltrated glioblastoma cells. Only NSCs and CAR T cells have been shown to migrate throughout the brain and attack distant foci of tumour cells^{126,131}. To aim to cure glioblastoma, a therapy must have the potential to penetrate deeply into the healthy tissue to selectively kill glioma cells. A deeper understanding of

NSC therapy, CAR T cells and the infiltration of glioblastoma itself is needed to increase the potential of these treatments.

Glioblastoma is an immunologically ‘cold’ tumour owing to low infiltration of T cells, and has shown a poor response to immunotherapies⁷⁸. Aside from the direct antitumour effects, local therapy might induce and enhance a local immune response. Cloughesy et al. showed that neoadjuvant anti-PD1 therapy combined with surgery improved survival outcomes¹³⁸. Local therapy can further enhance and prolong the inflammatory response after surgery, as seen in magnetic thermotherapy³⁰, PDT⁴³, IL-12 adenoviral therapy⁸⁹ and G207 therapy¹⁰⁴. Combination of these approaches with systemic checkpoint inhibition therapies could produce synergistic effects — a possibility that is being studied in many ongoing phase I and II trials (Supplementary Tables 1–5).

Local therapy could provide a first-line treatment option in patients with limited surgical possibilities. LITT and CED of chemotherapeutics and viral therapies might offer an alternative to surgery, although further optimization of the current high risk of adverse events and worsening of symptoms — albeit often transient — is warranted. At standard doses, brachytherapy does not seem to provide additional benefits, and although higher dosing could be feasible, studies have shown an unacceptable increase in toxicity and adverse events¹³⁹, without improvements in outcomes¹⁴⁰, when large local doses are administered.

Local delivery might also improve the efficacy of therapies such as bevacizumab that have shown limited benefits when administered systemically⁶⁶. Even the efficacy of current therapeutics such as temozolamide may be improved when delivered locally, and a clinical trial of intra-arterial delivery of this drug (NCT01180816) has recently finished including patients.

In the laboratory, various new techniques and therapies are being developed. New methods of delivery such as hydrogels¹⁴¹, nanoliposomal packaging¹⁴², polymeric microspheres¹⁴³ and cannabinoid microparticles¹⁴⁴ have all shown promise for delivering therapeutics to the tumour. The arsenal of therapeutics is also expanding. Bacterial carriers¹⁴⁵, RNA interference therapeutics¹⁴⁶ and high-frequency irreversible electroporation¹⁴⁷ have been tested in preclinical models and are awaiting translation to the clinic.

The preliminary successes of local therapy in patients will hopefully encourage the development of novel techniques and therapeutics. Neurosurgeons, neurologists, oncologists and other clinicians should be involved in the development of new therapies as early as possible to improve applicability to patients with glioblastoma, translation to the clinic and design of phase I and II trials. Although many innovative phase I and II trials are already being conducted, few therapies have been compared with the standard of care in randomized phase III trials. Currently, only one local therapy study, which is evaluating IORT plus standard of care (NCT02685605), is enrolling patients. Recruitment of enough patients to power a phase III trial remains a challenging and lengthy endeavour. Collaboration between governmental institutions, hospitals and countries should be encouraged and established in the early stages of treatment development to smooth the transition to larger cohorts and facilitate rapid expansion to phase III trials.

Glioblastoma remains challenging to treat, and many local therapies are currently in development. The future of glioblastoma treatment is likely to lie not in a singular approach but in combining local and systemic patient-tailored treatments to combat this lethal disease.

Published online: 11 March 2022

- Stupp, R. et al. Radiotherapy plus concomitant and adjuvant temozolamide for glioblastoma. *N. Engl. J. Med.* **352**, 987–996 (2005).
- Zhu, P., Du, X. L., Lu, G. & Zhu, J. J. Survival benefit of glioblastoma patients after FDA approval of temozolamide concomitant with radiation and bevacizumab: a population-based study. *Oncotarget* **8**, 44015–44031 (2017).
- Stupp, R. et al. Effects of radiotherapy with concomitant and adjuvant temozolamide versus radiotherapy alone on survival in glioblastoma in a randomised phase III study: 5-year analysis of the EORTC-NCIC trial. *Lancet Oncol.* **10**, 459–466 (2009).
- Stupp, R. et al. Maintenance therapy with tumor-treating fields plus temozolamide vs temozolamide alone for glioblastoma: a randomized clinical trial. *JAMA* **314**, 2535–2543 (2015).
- Mittal, S. et al. Alternating electric tumor treating fields for treatment of glioblastoma: rationale, preclinical, and clinical studies. *J. Neurosurg.* **128**, 414–421 (2018).
- Patel, A. P. et al. Single-cell RNA-seq highlights intratumoral heterogeneity in primary glioblastoma. *Science* **344**, 1396–1401 (2014).
- Brennan, C. W. et al. The somatic genomic landscape of glioblastoma. *Cell* **157**, 753 (2014).
- Broekman, M. L. et al. Multidimensional communication in the microenvirons of glioblastoma. *Nat. Rev. Neurol.* **14**, 482–495 (2018).
- Antunes, A. R. P. et al. Understanding the glioblastoma immune microenvironment as basis for the development of new immunotherapeutic strategies. *eLife* **9**, e52176 (2020).
- Jackson, M., Hassiotou, F. & Nowak, A. Glioblastoma stem-like cells: at the root of tumor recurrence and a therapeutic target. *Carcinogenesis* **36**, 177–185 (2014).
- Brandes, A. A. et al. Recurrence pattern after temozolamide concomitant with and adjuvant to radiotherapy in newly diagnosed patients with glioblastoma: correlation with MGMT promoter methylation status. *J. Clin. Oncol.* **27**, 1275–1279 (2009).
- McGirt, M. J. et al. Independent association of extent of resection with survival in patients with malignant brain astrocytoma: clinical article. *J. Neurosurg.* **110**, 156–162 (2009).
- Duffau, H. Long-term outcomes after supratotal resection of diffuse low-grade gliomas: a consecutive series with 11-year follow-up. *Acta Neurochir.* **158**, 51–58 (2016).
- De Leeuw, C. N. & Vogelbaum, M. A. Supratotal resection in glioma: a systematic review. *Neuro Oncol.* **21**, 179–188 (2019).
- Titsworth, W. L., Murad, G. J. A., Hoh, B. L. & Rahman, M. Fighting fire with fire: the revival of thermotherapy for gliomas. *Anticancer. Res.* **34**, 565–574 (2014).
- Watanabe, M., Tanaka, R., Hondo, H. & Kuroki, M. Effects of antineoplastic agents and hyperthermia on cytotoxicity toward chronically hypoxic glioma cells. *Int. J. Hyperthermia* **8**, 131–138 (1992).
- Menovsky, T., Beek, J. F., Van Gemert, M. J. C., Roux, F. X. & Bown, S. G. Interstitial laser thermotherapy in neurosurgery: a review. *Acta Neurochir.* **138**, 1019–1026 (1996).
- Man, J. et al. Hyperthermia sensitizes glioma stem-like cells to radiation by inhibiting AKT signaling. *Cancer Res.* **75**, 1760–1769 (2015).
- Schildkopf, P. et al. Biological rationales and clinical applications of temperature controlled hyperthermia – implications for multimodal cancer treatments. *Curr. Med. Chem.* **17**, 3045–3057 (2010).
- Frey, B. et al. Old and new facts about hyperthermia-induced modulations of the immune system. *Int. J. Hyperthermia* **28**, 528–542 (2012).
- Lee, I., Kalkanis, S. & Hadjipanayis, C. G. Stereotactic laser interstitial thermal therapy for recurrent high-grade gliomas. *Clin. Neurosurg.* **79**, S24–S34 (2016).
- Holste, K. G. & Orringer, D. A. Laser interstitial thermal therapy. *Neurooncol Adv.* **2**, vd2035 (2020).
- Mohammadi, A. M. et al. Upfront magnetic resonance imaging-guided stereotactic laser-ablation in newly diagnosed glioblastoma: a multicenter review of survival outcomes compared to a matched cohort of biopsy-only patients. *Clin. Neurosurg.* **85**, 762–772 (2019).
- Kamath, A. A. et al. Glioblastoma treated with magnetic resonance imaging-guided laser interstitial thermal therapy: safety, efficacy, and outcomes. *Clin. Neurosurg.* **84**, 836–843 (2019).
- Mohammadi, A. M. et al. The role of laser interstitial thermal therapy in enhancing progression-free survival of difficult-to-access high-grade gliomas: a multicenter study. *Cancer Med.* **3**, 971–979 (2014).
- Viozzi, I., Guberinic, A., Overduin, C. G., Rovers, M. M. & ter Laan, M. Laser interstitial thermal therapy in patients with newly diagnosed glioblastoma: a systematic review. *J. Clin. Med.* **10**, 355 (2021).
- Leuthardt, E. C., Voigt, J., Kim, A. H. & Sylvester, P. A single-center cost analysis of treating primary and metastatic brain cancers with either brain laser interstitial thermal therapy (LITT) or craniotomy. *Pharmacoecon. Open* **1**, 53–63 (2017).

28. Barnett, G. H., Voigt, J. D. & Alhuwalia, M. S. A systematic review and meta-analysis of studies examining the use of brain laser interstitial thermal therapy versus craniotomy for the treatment of high-grade tumors in or near areas of eloquence: an examination of the extent of resection and major complication rates associated with each type of surgery. *Stereotact. Funct. Neurosurg.* **94**, 164–173 (2016).
29. Maier-Hauff, K. et al. Efficacy and safety of intratumoral thermotherapy using magnetic iron-oxide nanoparticles combined with external beam radiotherapy on patients with recurrent glioblastoma multiforme. *J. Neurooncol.* **103**, 317–324 (2011).
30. Grauer et al. Combined intracavitary thermotherapy with iron oxide nanoparticles and radiotherapy as local treatment modality in recurrent glioblastoma patients. *J. Neurooncol.* **141**, 83–94 (2019).
31. Brown, N. F., Carter, T. J., Ottaviani, D. & Mulholland, P. Harnessing the immune system in glioblastoma. *Br. J. Cancer* **119**, 1171–1181 (2018).
32. Meng, Y., Hynynen, K. & Lipsman, N. Applications of focused ultrasound in the brain: from thermoablation to drug delivery. *Nat. Rev. Neuro.* **17**, 7–22 (2021).
33. Bunevicius, A., McDannold, N. J. & Golby, A. J. Focused ultrasound strategies for brain tumor therapy. *Oper. Neurosurg.* **19**, 9–18 (2020).
34. Elias, W. J. et al. A randomized trial of focused ultrasound thalamotomy for essential tremor. *N. Engl. J. Med.* **375**, 730–739 (2016).
35. Guthkelch, A. N. et al. Treatment of malignant brain tumors with focused ultrasound hyperthermia and radiation: results of a phase I trial. *J. Neurooncol.* **10**, 271–284 (1991).
36. Castano, A. P., Demidova, T. N. & Hamblin, M. R. Mechanisms in photodynamic therapy: part one—photosensitizers, photochemistry and cellular localization. *Photodiagnosis Photodyn. Ther.* **1**, 279–293 (2004).
37. Castano, A. P., Demidova, T. N. & Hamblin, M. R. Mechanisms in photodynamic therapy: part two—cellular signaling, cell metabolism and modes of cell death. *Photodiagnosis Photodyn. Ther.* **2**, 1–23 (2005).
38. Fingar, V. H. Vascular effects of photodynamic therapy. *J. Clin. Laser Med. Surg.* **14**, 323–328 (1996).
39. Li, F. et al. Photodynamic therapy boosts anti-glioma immunity in mice: a dependence on the activities of T cells and complement C3. *J. Cell. Biochem.* **112**, 3035–3043 (2011).
40. Bellnier, D. A. et al. Clinical pharmacokinetics of the PDT photosensitizers porfimer sodium (Photofrin), 2-[1-hexyloxyethyl]-2-devinyl pyropheophorbide-a (Photoclor) and 5-ALA-induced protoporphyrin IX. *Lasers Surg. Med.* **38**, 439–444 (2006).
41. Stummer, W. et al. Fluorescence-guided surgery with 5-aminolevulinic acid for resection of malignant glioma: a randomised controlled multicentre phase III trial. *Lancet Oncol.* **7**, 392–401 (2006).
42. Eljamel, M. S., Goodman, C. & Moseley, H. ALA and Photofrin® fluorescence-guided resection and repetitive PDT in glioblastoma multiforme: a single centre phase III randomised controlled trial. *Lasers Med. Sci.* **23**, 361–367 (2008).
43. Schipmann, S. et al. Combination of ALA-induced fluorescence-guided resection and intraoperative open photodynamic therapy for recurrent glioblastoma: case series on a promising dual strategy for local tumor control. *J. Neurosurg.* **134**, 426–436 (2020).
44. Linde, M. E. Van et al. Treatment outcome of patients with recurrent glioblastoma multiforme: a retrospective multicenter analysis. *J. Neurooncol.* **135**, 183–192 (2017).
45. Wang, H.-W. et al. Broadband reflectance measurements of light penetration, blood oxygenation, hemoglobin concentration, and drug concentration in human intraperitoneal tissues before and after photodynamic therapy. *J. Biomed. Opt.* **10**, 014004 (2005).
46. Akimoto, J. et al. First autopsy analysis of the efficacy of intra-operative additional photodynamic therapy for patients with glioblastoma. *Brain Tumor Pathol.* **36**, 144–151 (2019).
47. Vermandel, M. et al. Standardized intraoperative 5-ALA photodynamic therapy for newly diagnosed glioblastoma patients: a preliminary analysis of the INDYGO clinical trial. *J. Neurooncol.* **152**, 501–514 (2021).
48. Jain, R. K. Delivery of novel therapeutic agents in tumors: physiological barriers and strategies. *J. Natl Cancer Inst.* **81**, 570–576 (1989).
49. Jahangiri, A. et al. Convection-enhanced delivery in glioblastoma: a review of preclinical and clinical studies. *J. Neurosurg.* **126**, 191–200 (2017).
50. Kunwar, S. et al. Phase III randomized trial of CED of IL13-PE38QQR vs Gliadel wafers for recurrent glioblastoma. *Neuro. Oncol.* **12**, 871–881 (2010).
51. Jain, R. K. Vascular and interstitial barriers to delivery of therapeutic agents in tumors. *Cancer Metastasis Rev.* **9**, 253–266 (1990).
52. Smith, J. H. & Humphrey, J. A. C. Interstitial transport and transvascular fluid exchange during infusion into brain and tumor tissue. *Microvasc. Res.* **73**, 58–73 (2007).
53. Gimenez, F. et al. Image-guided convection-enhanced delivery of GDNF protein into monkey putamen. *Neuroimage* **54** (Suppl. 1), 189–195 (2011).
54. Astarly, G. W., Kantorovich, S., Carney, P. R., Mareci, T. H. & Sarntinoranont, M. Regional convection-enhanced delivery of gadolinium-labeled albumin in the rat hippocampus in vivo. *J. Neurosci. Methods* **187**, 129–137 (2010).
55. Sampson, J. H. et al. Colocalization of gadolinium-diethylene triamine pentaacetic acid with high-molecular-weight molecules after intracerebral convection-enhanced delivery in humans. *Neurosurgery* **69**, 668–676 (2011).
56. Saito, R. et al. Regression of recurrent glioblastoma infiltrating the brainstem after convection-enhanced delivery of nimustine hydrochloride: case report. *J. Neurosurg. Pediatr.* **7**, 522–526 (2011).
57. Saito, R. et al. Phase I trial of convection-enhanced delivery of nimustine hydrochloride (ACNU) for brainstem recurrent glioma. *Neurooncol. Adv.* **2**, vdaa033 (2020).
58. Haar, P. J. et al. Modelling convection-enhanced delivery in normal and oedematous brain. *J. Med. Eng. Technol.* **38**, 76–84 (2014).
59. White, E. et al. An evaluation of the relationships between catheter design and tissue mechanics in achieving high-flow convection-enhanced delivery. *J. Neurosci. Methods* **199**, 87–97 (2011).
60. Westphal, M. et al. A phase 3 trial of local chemotherapy with biodegradable carmustine (BCNU) wafers (Gliadel wafers) in patients with primary malignant glioma. *Neuro. Oncol.* **5**, 79–88 (2003).
61. Bregy, A. et al. The role of Gliadel wafers in the treatment of high-grade gliomas. *Expert Rev. Anticancer Ther.* **13**, 1453–1461 (2013).
62. De Bonis, P. et al. Safety and efficacy of Gliadel wafers for newly diagnosed and recurrent glioblastoma. *Acta Neurochir.* **154**, 1371–1378 (2012).
63. Tsai, N. M. et al. The natural compound n-butylidenephthalide derived from *Angelica sinensis* inhibits malignant brain tumor growth in vitro and in vivo. *J. Neurochem.* **99**, 1251–1262 (2006).
64. Yang, D.-Y. et al. Enhanced antitumor effects of radiotherapy combined local nimustine delivery rendezvousing with oral temozolomide chemotherapy in glioblastoma patients. *J. Cancer Res. Ther.* **14**, 78 (2018).
65. Wilson, C. B. Chemotherapy of brain tumors by continuous arterial infusion. *Surgery* **55**, 640–653 (1964).
66. D'Amico, R. S. et al. Super selective intra-arterial cerebral infusion of modern chemotherapeutics after blood–brain barrier disruption: where are we now, and where we are going. *J. Neurooncol.* **147**, 261–278 (2020).
67. Karmur, B. S. et al. Blood–brain barrier disruption in neuro-oncology: strategies, failures, and challenges to overcome. *Front. Oncol.* **10**, 563840 (2020).
68. Bookvar, J. A. et al. Safety and maximum tolerated dose of superselective intraarterial cerebral infusion of bevacizumab after osmotic blood-brain barrier disruption for recurrent malignant glioma: clinical article. *J. Neurosurg.* **114**, 624–632 (2011).
69. Galla, N. et al. Apparent diffusion coefficient changes predict survival after intra-arterial bevacizumab treatment in recurrent glioblastoma. *Neuroradiology* **59**, 499–505 (2017).
70. Shin, B. J., Burkhardt, J.-K., Riina, H. A. & Bookvar, J. A. Superselective intra-arterial cerebral infusion of novel agents after blood–brain barrier disruption for the treatment of recurrent glioblastoma multiforme: a technical case series. *Neurosurg. Clin.* **23**, 323–329 (2012).
71. Chakraborty, S. et al. Superselective intraarterial cerebral infusion of cetuximab after osmotic blood/brain barrier disruption for recurrent malignant glioma: phase I study. *J. Neurooncol.* **128**, 405–415 (2016).
72. Fortin, D., Morin, P. A., Belzile, F., Mathieu, D. & Paré, F. M. Intra-arterial carboplatin as a salvage strategy in the treatment of recurrent glioblastoma multiforme. *J. Neurooncol.* **119**, 397–403 (2014).
73. Petr, J. et al. Early and late effects of radiochemotherapy on cerebral blood flow in glioblastoma patients measured with non-invasive perfusion MRI. *Radiother. Oncol.* **118**, 24–28 (2016).
74. Svensson, S. F. et al. MR elastography-based tissue stiffness in glioblastomas is associated with reduced cerebral blood flow. Preprint at *medRxiv* <https://doi.org/10.1101/2021.06.11.21258742> (2021).
75. Chow, K. L. et al. Prognostic factors in recurrent glioblastoma multiforme and anaplastic astrocytoma treated with selective intra-arterial chemotherapy. *Am. J. Neuroradiol.* **21**, 471–478 (2000).
76. Joshi, S. et al. Transient cerebral hypoperfusion assisted intraarterial cationic liposome delivery to brain tissue. *J. Neurooncol.* **118**, 73–82 (2014).
77. Riina, H. A. et al. Balloon-assisted superselective intra-arterial cerebral infusion of bevacizumab for malignant brainstem glioma: a technical note. *Interv. Neuroradiol.* **16**, 71–76 (2010).
78. Jackson, C. M., Choi, J. & Lim, M. Mechanisms of immunotherapy resistance: lessons from glioblastoma. *Nat. Immunol.* **20**, 1100–1109 (2019).
79. McGranahan, T., Therkelsen, K. E., Ahmad, S. & Nagpal, S. Current state of immunotherapy for treatment of glioblastoma. *Curr. Treat. Options Oncol.* **20**, 24 (2019).
80. Weller, M. & Le Rhun, E. Immunotherapy for glioblastoma: quo vadis? *Nat. Rev. Clin. Oncol.* **16**, 405–406 (2019).
81. Chiocca, E. A., Nassiri, F., Wang, J., Peruzzi, P. & Zadeh, G. Viral and other therapies for recurrent glioblastoma: is a 24-month durable response unusual? *Neuro. Oncol.* **21**, 14–25 (2019).
82. Auffinger, B., Ahmed, A. U. & Lesniak, M. S. Oncolytic virotherapy for malignant glioma: translating laboratory insights into clinical practice. *Front. Oncol.* **3**, 32 (2013).
83. Martikainen, M. & Essand, M. Virus-based immunotherapy of glioblastoma. *Cancers* **11**, 186 (2019).
84. Harsh, G. R. et al. Thymidine kinase activation of ganciclovir in recurrent malignant gliomas: a gene-marking and neuropathological study. *J. Neurosurg.* **92**, 804–811 (2000).
85. Rainov, N. G. et al. Temozolomide enhances herpes simplex virus thymidine kinase/ganciclovir therapy of malignant glioma. *Cancer Gene Ther.* **8**, 662–668 (2001).
86. Nestler, U. et al. The combination of adenoviral HSV TK gene therapy and radiation is effective in athymic mouse glioblastoma xenografts without increasing toxic side effects. *J. Neurooncol.* **67**, 177–188 (2004).
87. Wheeler, L. A. et al. Phase II multicenter study of gene-mediated cytotoxic immunotherapy as adjuvant to surgical resection for newly diagnosed malignant glioma. *Neuro. Oncol.* **18**, 1137–1145 (2016).
88. Ji, N. et al. Adenovirus-mediated delivery of herpes simplex virus thymidine kinase administration improves outcome of recurrent high-grade glioma. *Oncotarget* **7**, 4369–4378 (2016).
89. Chiocca, E. A. et al. Regulatable interleukin-12 gene therapy in patients with recurrent high-grade glioma: results of a phase 1 trial. *Sci. Transl. Med.* **11**, eaaw5680 (2019).
90. Trinchieri, G. Interleukin-12 and the regulation of innate resistance and adaptive immunity. *Nat. Rev. Immunol.* **3**, 133–146 (2003).
91. Zhang, L. et al. Tumor-infiltrating lymphocytes genetically engineered with an inducible gene encoding interleukin-12 for the immunotherapy of metastatic melanoma. *Clin. Cancer Res.* **21**, 2278–2288 (2015).
92. Car, B. D., Eng, V. M., Lipman, J. M. & Anderson, T. D. The toxicology of interleukin-12: a review. *Toxicol. Pathol.* **27**, 58–63 (1999).
93. Cai, H. et al. Plasma pharmacokinetics of vevledimex, a small-molecule activator ligand for a proprietary gene therapy promoter system, in healthy subjects. *Clin. Pharmacol. Drug Dev.* **6**, 246–257 (2017).
94. Ostertag, D. et al. Brain tumor eradication and prolonged survival from intratumoral conversion of 5-fluorocytosine to 5-fluorouracil using a nonlytic retroviral replicating vector. *Neuro Oncol.* **14**, 145–159 (2012).
95. Cloughesy, T. F. et al. Phase 1 trial of vocimogene amiretrorepvec and 5-fluorocytosine for recurrent high-grade glioma. *Sci. Transl. Med.* **8**, 341ra75 (2016).
96. Desjardins, A. et al. Recurrent glioblastoma treated with recombinant poliovirus. *N. Engl. J. Med.* **379**, 150–161 (2018).

97. Brown, M. C. et al. Cancer immunotherapy with recombinant poliovirus induces IFN-dominant activation of dendritic cells and tumor antigen-specific CTLs. *Sci. Transl. Med.* **9**, eaan4220 (2017).
98. Lang, F. F. et al. Phase I study of DNX-2401 (delta-24-RGD) oncolytic adenovirus: replication and immunotherapeutic effects in recurrent malignant glioma. *J. Clin. Oncol.* **36**, 1419–1427 (2018).
99. Maher, E. A. et al. Malignant glioma: genetics and biology of a grave matter. *Genes Dev.* **15**, 1311–1333 (2001).
100. Fueyo, J. et al. Preclinical characterization of the anti-glioma activity of a tropism-enhanced adenovirus targeted to the retinoblastoma pathway. *J. Natl Cancer Inst.* **95**, 652–660 (2003).
101. Mineta, T., Rabkin, S. D., Yazaki, T., Hunter, W. D. & Martuza, R. L. Attenuated multi-mutated herpes simplex virus-1 for the treatment of malignant gliomas. *Nat. Med.* **1**, 938–943 (1995).
102. Markert, J. M. et al. A phase I trial of oncolytic HSV-1, G207, given in combination with radiation for recurrent GBM demonstrates safety and radiographic responses. *Mol. Ther.* **22**, 1048–1055 (2014).
103. Friedman, G. K. et al. Enhanced sensitivity of patient-derived pediatric high-grade brain tumor xenografts to oncolytic HSV-1 virotherapy correlates with nectin-1 expression. *Sci. Rep.* **8**, 13930 (2018).
104. Friedman, G. K. et al. Oncolytic HSV-1 G207 immunovirotherapy for pediatric high-grade gliomas. *N. Engl. J. Med.* **384**, 1613–1622 (2021).
105. Liu, E. K., Yu, S., Sulman, E. P. & Kurz, S. C. Racial and socioeconomic disparities differentially affect overall and cause-specific survival in glioblastoma. *J. Neurooncol.* **149**, 55–64 (2020).
106. Rainov, N. G. A phase III clinical evaluation of herpes simplex virus type 1 thymidine kinase and ganciclovir gene therapy as an adjuvant to surgical resection and radiation in adults with previously untreated glioblastoma multiforme. *Hum. Gene Ther.* **11**, 2389–2401 (2000).
107. Kawakami, M., Kawakami, K. & Puri, R. K. Intratumor administration of interleukin 13 receptor-targeted cytotoxin induces apoptotic cell death in human malignant glioma tumor xenografts. *Mol. Cancer Ther.* **1**, 999–1007 (2002).
108. Krieg, A. M. Antitumor applications of stimulating Toll-like receptor 9 with CpG oligodeoxynucleotides. *Curr. Oncol. Rep.* **6**, 88–95 (2004).
109. Meng, Y. et al. Expression of TLR9 within human glioblastoma. *J. Neurooncol.* **88**, 19–25 (2008).
110. Andaloussi, S. E. L., Mäger, I., Breakefield, X. O. & Wood, M. J. Extracellular vesicles: biology and emerging therapeutic opportunities. *Nat. Rev. Drug Discov.* **12**, 347–357 (2013).
111. Carpentier, A. et al. Intracerebral administration of CpG oligonucleotide for patients with recurrent glioblastoma: a phase II study. *Neuro. Oncol.* **12**, 401–408 (2010).
112. Ursu, R. et al. Intracerebral injection of CpG oligonucleotide for patients with de novo glioblastoma—a phase II multicentric, randomised study. *Eur. J. Cancer* **73**, 30–37 (2017).
113. Nduom, E. K., Weller, M. & Heimberger, A. B. Immunosuppressive mechanisms in glioblastoma. *Neuro Oncol.* **17** (Suppl. 7), vii9–vii14 (2015).
114. Mann, J., Ramakrishna, R., Magge, R. & Wernicke, A. G. Advances in radiotherapy for glioblastoma. *Front. Neurol.* **8**, 748 (2018).
115. Barbarite, E. et al. The role of brachytherapy in the treatment of glioblastoma multiforme. *Neurosurg. Rev.* **40**, 195–211 (2017).
116. Bartek, J. et al. Receipt of brachytherapy is an independent predictor of survival in glioblastoma in the Surveillance, Epidemiology, and End Results database. *J. Neurooncol.* **145**, 75–83 (2019).
117. Field, K. M. et al. Clinical trial participation and outcome for patients with glioblastoma: multivariate analysis from a comprehensive dataset. *J. Clin. Neurosci.* **20**, 783–789 (2013).
118. Skaga, E. et al. Real-world validity of randomized controlled phase III trials in newly diagnosed glioblastoma: to whom do the results of the trials apply? *Neurooncol.* **Adv.** **3**, vdab008 (2021).
119. Schwartz, C. et al. Outcome and toxicity profile of salvage low-dose-rate iodine-125 stereotactic brachytherapy in recurrent high-grade gliomas. *Acta Neurochir.* **157**, 1757–1764 (2015).
120. Kickingeder, P. et al. Low-dose rate stereotactic iodine-125 brachytherapy for the treatment of inoperable primary and recurrent glioblastoma: single-center experience with 201 cases. *J. Neurooncol.* **120**, 615–623 (2014).
121. Phillips, W. T. et al. Rhenium-186 liposomes as convection-enhanced nanoparticle brachytherapy for treatment of glioblastoma. *Neuro. Oncol.* **14**, 416–425 (2012).
122. Pilar, A., Gupta, M., Ghosh Laskar, S. & Laskar, S. Intraoperative radiotherapy: review of techniques and results. *Ecancermedicalscience* **11**, 750 (2017).
123. Sarria, G. R. et al. Intraoperative radiotherapy for glioblastoma: an international pooled analysis. *Radiother. Oncol.* **142**, 162–167 (2020).
124. Aboody, K. S. et al. Neural stem cell-mediated enzyme/prodrug therapy for glioma: preclinical studies. *Sci. Transl. Med.* **5**, 184ra59 (2013).
125. Pacioni, S. et al. Human mesenchymal stromal cells inhibit tumor growth in orthotopic glioblastoma xenografts. *Stem Cell Res. Ther.* **8**, 53 (2017).
126. Portnow, J. et al. Neural stem cell-based anticancer gene therapy: a first-in-human study in recurrent high-grade glioma patients. *Clin. Cancer Res.* **23**, 2951–2960 (2017).
127. Kim, S. U. Human neural stem cells genetically modified for brain repair in neurological disorders. *Neuropathology* **24**, 159–171 (2004).
128. Fares, J. et al. Neural stem cell delivery of an oncolytic adenovirus in newly diagnosed malignant glioma: a first-in-human, phase 1, dose-escalation trial. *Lancet Oncol.* **22**, 1103–1114 (2021).
129. Ahmed, A. U. et al. A preclinical evaluation of neural stem cell-based cell carrier for targeted anti-glioma oncolytic virotherapy. *J. Natl Cancer Inst.* **105**, 968–977 (2013).
130. Salinas, R. D., Durgin, J. S. & O'Rourke, D. M. Potential of glioblastoma-targeted chimeric antigen receptor (CAR) T-cell therapy. *CNS Drugs* **34**, 127–145 (2020).
131. Brown, C. E. et al. Regression of glioblastoma after chimeric antigen receptor T-cell therapy. *N. Engl. J. Med.* **375**, 2561–2569 (2016).
132. Spaeth, E., Klopp, A., Dembinski, J., Andreeff, M. & Marini, F. Inflammation and tumor microenvironments: defining the migratory itinerary of mesenchymal stem cells. *Gene Ther.* **15**, 730–738 (2008).
133. Choi, S. H. et al. Tumor resection recruits effector T cells and boosts therapeutic efficacy of encapsulated stem cells expressing IFN β in glioblastomas. *Clin. Cancer Res.* **23**, 7047–7058 (2017).
134. Alayo, Q. A. et al. Glioblastoma infiltration of both tumor- and virus-antigen specific cytotoxic T cells correlates with experimental virotherapy responses. *Sci. Rep.* **10**, 5095 (2020).
135. Neftel, C. et al. An integrative model of cellular states, plasticity, and genetics for glioblastoma. *Cell* **178**, 835–849.e21 (2019).
136. Felsberg, J. et al. Epidermal growth factor receptor variant III (EGFRvIII) positivity in EGFR-amplified glioblastomas: prognostic role and comparison between primary and recurrent tumors. *Clin. Cancer Res.* **23**, 6846–6855 (2017).
137. Chongsathidkiet, P. et al. Sequestration of T cells in bone marrow in the setting of glioblastoma and other intracranial tumors. *Nat. Med.* **24**, 1459–1468 (2018).
138. Cloughesy, T. F. et al. Neoadjuvant anti-PD-1 immunotherapy promotes a survival benefit with intratumoral and systemic immune responses in recurrent glioblastoma. *Nat. Med.* **25**, 477–486 (2019).
139. Chen, A. M. et al. Phase I trial of gross total resection, permanent iodine-125 brachytherapy, and hyperfractionated radiotherapy for newly diagnosed glioblastoma multiforme. *Int. J. Radiat. Oncol. Biol. Phys.* **69**, 825–830 (2007).
140. Cabrera, A. R. et al. Radiation therapy for glioblastoma: executive summary of an American Society for Radiation Oncology evidence-based clinical practice guideline. *Pract. Radiat. Oncol.* **6**, 217–225 (2016).
141. Puente, Pdela et al. Injectable hydrogels for localized chemotherapy and radiotherapy in brain tumors. *J. Pharm. Sci.* **107**, 922–933 (2018).
142. Chen, P. Y. et al. Comparing routes of delivery for nanoliposomal irinotecan shows superior anti-tumor activity of local administration in treating intracranial glioblastoma xenografts. *Neuro Oncol.* **15**, 189–197 (2013).
143. Floyd, J. A., Galperin, A. & Ratner, B. D. Drug encapsulated polymeric microspheres for intracranial tumor therapy: a review of the literature. *Adv. Drug Deliv. Rev.* **91**, 23–37 (2015).
144. Hernán Pérez de la Ossa, D. et al. Local delivery of cannabinoid-loaded microparticles inhibits tumor growth in a murine xenograft model of glioblastoma multiforme. *PLoS ONE* **8**, 2–9 (2013).
145. Mehta, N. et al. Bacterial carriers for glioblastoma therapy. *Mol. Ther. Oncolytics* **4**, 1–17 (2017).
146. Cohen, Z. R. et al. Localized RNAi therapeutics of chemoresistant grade IV glioma using hyaluronan-grafted lipid-based nanoparticles. *ACS Nano* **9**, 1581–1591 (2015).
147. Sharabi, S. et al. The application of point source electroporation and chemotherapy for the treatment of glioma: a randomized controlled rat study. *Sci. Rep.* **10**, 2178 (2020).
148. Giuliano, A. R. et al. Participation of minorities in cancer research: the influence of structural, cultural, and linguistic factors. *Ann. Epidemiol.* **10**, S22–S34 (2000).
149. Pitter, K. L. et al. Corticosteroids compromise survival in glioblastoma. *Brain* **139**, 1458–1471 (2016).
150. Gorlia, T. et al. New prognostic factors and calculators for outcome prediction in patients with recurrent glioblastoma: a pooled analysis of EORTC Brain Tumour Group phase I and II clinical trials. *Eur. J. Cancer* **48**, 1176–1184 (2012).

Acknowledgements

The authors thank M. E. Haeflich for proofreading this manuscript for typographical and grammatical errors; skilled editorial assistance from S. McDavitt; and insights from X. Breakefield. M.L.D.B. is supported by grant NIH NCI R35 CA232103. T.S.v.S. is supported by grants from the Bontius Stichting, the Nijbakker-Morra Fund, Foundation Vrijvrouwe van Renswoude and the Bekker-la Bastide Fund. T.S.v.S. and E.A.C. are supported by NIH grant P01 CA069246.

Author contributions

T.S.v.S. researched data for the article. All authors contributed substantially to discussion of the content. T.S.v.S. and M.L.D.B. wrote the article. All authors reviewed and/or edited the manuscript before submission.

Competing interests

E.A.C. is currently an advisor to Advantagene, Alcyone Biosciences, Insightec, DNATrix, Immunomic Therapeutics, Seneca Therapeutics, GlaxoSmithKline and Voyager Therapeutics and has equity interest in DNATrix, Immunomic Therapeutics and Seneca Therapeutics; he has also advised Oncorus, Merck, Tocagen, Ziopharm, Stemgen, NanoTx., Ziopharm Oncology, Cerebral Therapeutics, Genenta, Merck, Janssen, Karcinolysis, Shanghai Biotech and Sangamo Therapeutics. He has received research support from the NIH, the US Department of Defense, the American Brain Tumor Association, the National Brain Tumor Society, the Alliance for Cancer Gene Therapy, the Neurosurgical Research Education Foundation, Advantagene, NewLink Genetics and Amgen. He is also a named inventor on patents related to oncolytic HSV-1 and non-coding RNAs. The other authors declare no competing interests.

Peer review information

Nature Reviews Neurology thanks C. Herold-Mende and the other, anonymous, reviewer(s) for their contribution to the peer review of this work.

Publisher's note

Springer Nature remains neutral with regard to jurisdictional claims in published maps and institutional affiliations.

Review criteria

In December 2020, we searched PubMed and Embase for studies utilizing any form of local therapy in glioblastoma. Keywords, Mesh terms and Emtree terms including “glioblastoma”, “glioma”, “local therapy”, “localized therapy”, “convection enhanced delivery”, “thermotherapy”, “wafer”, “brachytherapy”, “photodynamic therapy” and their synonyms were combined to form our search. Titles and abstracts were screened for relevant articles and studies. References from full-text articles were screened for additional studies. Articles had to be written in English and published within the past 20 years. Studies performed before implementation of the Stupp protocol were excluded, unless deemed relevant to current studies or patient care. Case reports were also excluded. Additional papers were recommended by all authors. For current clinical trials, ClinicalTrials.gov was searched for disease “glioblastoma” and “glioma”, and all trials with status “not yet recruiting”, “recruiting”, “enrolling by invitation”, “active, not recruiting”, or “available”.

Supplementary information

The online version contains supplementary material available at <https://doi.org/10.1038/s41582-022-00621-0>.

© Springer Nature Limited 2022